

Case Report

A Postmortem Examination of Poly-L Lactic Acid Interference Screws 4 Months After Implantation During Anterior Cruciate Ligament Reconstruction

David A. McGuire, M.D., F. Alan Barber, M.D., Sara Milchgrub, M.D.,
and Jeffrey C. Wolchok, M.S.

Abstract: This is a report of a postmortem examination of an implanted bioabsorbable interference screw used for patellar tendon graft fixation during anterior cruciate ligament reconstruction. Examination was conducted 4 months after implantation. Examination included radiographic, arthroscopic, and magnetic resonance evaluations as well as histologic and mechanical pullout testing. Examination showed no evidence of tunnel widening, lytic bone changes, or inflammatory or foreign body reaction. Pullout and histologic testing indicated that appropriate bone plug incorporation was occurring. We believe the results of this case suggest that the use of bioabsorbable poly-L lactic acid interference screws is a safe and efficacious alternative to metallic screws during anterior cruciate ligament reconstruction. **Key Words:** Anterior cruciate ligament—Interference fixation screw—Bioabsorbable—BioScrew—Poly-L lactic acid.

Patella tendon autograft anterior cruciate ligament (ACL) reconstruction with bioabsorbable interference screw fixation is a commonly performed procedure. However, it is rare when arthroscopists have the opportunity to study in depth the postoperative status of such a reconstruction. As a result of a tragic accident that claimed the life of a patient 4 months after an ACL reconstruction, we were afforded the opportunity to not only obtain radiographic, arthroscopic, and magnetic resonance imaging (MRI) evaluations of a bioabsorbable interference screw ACL reconstruction, but histologic and mechanical testing data as well. We are unaware of any other report of this type in the literature.

From Private Practice, Anchorage, Alaska (D.A.M.); Plano Orthopaedic and Sports Medicine Center, Plano, Texas (F.A.B.); University of Texas Southwestern Medical Center, Dallas, Texas (S.M.); and Anchorage Orthopedic Labs, Anchorage, Alaska (J.C.W.), U.S.A.

Address correspondence and reprint requests to Jeffrey C. Wolchok, c/o David A. McGuire, M.D., Anchorage Orthopaedic and Sports Medicine Research Center, 4100 Lake Otis Pkwy, Suite 320, Anchorage, AK 99508, U.S.A. E-mail: jeff@mcguiremd.com

© 2001 by the Arthroscopy Association of North America

0749-8063/01/1709-2657\$35.00/0

doi:10.1053/jars.2001.22421

CASE REPORT

Case History

A 31-year-old man reported to the clinic 2 days after injuring his knee while skiing. He reported initial sharp pain, lateral joint pain, and decreased knee flexion. The patient stated that he could not “trust” the knee. Physical examination was indicative of an ACL tear with a grade 2+ Lachman test and a 2+ flexion rotation drawer test. No other ligamentous laxity was noted. Based on this physical examination, a preliminary diagnosis of an isolated ACL tear was made.

The findings and treatment options were discussed with the patient. Surgical options included arthroscopic reconstruction of the ligament with either a patellar tendon autograft or patellar tendon allograft. Conservative management through physical therapy and a possible reduction in activities was also discussed. The patient was physically active and wished to maintain a high level of activity and, therefore, he elected to have the ACL reconstructed with a patellar tendon autograft.

Surgery was performed 1 month after his injury.

Arthroscopy revealed a complete tear of the ACL at its femoral attachment. The arthroscopic Lachman test¹ was positive. Further arthroscopic examination revealed no additional injuries. The tibial-femoral and patellar-femoral chondral surfaces were normal. Following the arthroscopic examination, the torn ACL was resected and a notchplasty and roofplasty were performed with a motorized burr. The over-the-top position on the femur was visualized and the periosteum elevated.

The middle third of the patellar tendon was harvested through 2 1-inch incisions. The tibial tunnel was positioned with the aid of a commercially available drill guide (Frontier; DePuy, Tracy, CA). After placement of the tibial tunnel, an endoscopic femoral aimer (Paramax; Linvatec, Largo, FL) was used to place the femoral tunnel just anterior to the over-the-top position. The prepared graft was advanced through the tibial tunnel into the femoral tunnel and fixed with a 7- × 25-mm bioabsorbable interference screw (BioScrew; Linvatec). Traction was applied to the graft distally and isometry was evaluated. Neither pistoning nor impingement of the graft was identified as the knee was cycled between 0° and 90° of flexion. At this point, the tibial portion was fixed with a 7 × 25 mm BioScrew. The tourniquet time was 29 minutes. The procedure was accomplished on an outpatient basis and the patient returned home that day without incident.

The patient participated in an exercise program consisting of office-based and home-based physical therapy. The initial physical therapy concentrated on restoring range of motion and controlling swelling. Later closed-chain thigh strengthening exercises and stationary bicycling were added. At 2 weeks, the Lachman test was negative and swelling was minimal. At 5 weeks, extension was 0° and flexion was 142° with no swelling. The patient failed to make subsequently scheduled visits. Four months postoperatively, the patient drowned in a kayaking accident. The consent of the family was obtained to procure the operative knee for freezing and later analysis. Tissue was procured with the assistance of the local tissue procurement agency (Life Alaska, Anchorage, AK).

Postmortem Examination

Conventional spin echo, proton density frontal and sagittal view MRI sequences were obtained. Additionally, anteroposterior and frontal view plain-film radiographs and axial computed tomographic views were taken. The images were jointly reviewed by 2 authors, both orthopaedic surgeons. The screws were still

clearly visible in both the femoral and tibial tunnels. No screw resorption was observed. The screws appeared well seated between the autologous bone plug and the surrounding bone. There was no evidence of lytic bone changes, tunnel widening, cyst formation, or fluid accumulation surrounding the screw (Fig 1).

After imaging, a relook arthroscopy was conducted by the author who had initially performed the ACL reconstruction. Arthroscopy revealed a viable graft. The femoral attachment was visualized and no inflammation was evident (Fig 2). Both the chondral and synovial surfaces appeared normal with no evidence of chondral degeneration or synovitis, respectively (Fig 3).

Load-to-failure testing of the tibial ligament insertion was conducted. The tibia and reconstructed graft were sectioned from the femur. The resulting bone, screw, and graft complex was mounted in a commercially available load stand (MTS, Minneapolis, MN) with the aid of a specially designed test fixture. A tensile load was applied to the grafts in a direction paralleling the tibial tunnel. Freeze clamps were used to connect the free end of the graft to the load stand. A 10-N preload was applied to the graft followed by tensile loading at a constant strain rate of 8.5 mm/second until failure occurred. A load of 1,130 N was reached before failure occurred at the junction between the freeze clamps and graft.

The distal femur was fixed in 10% formalin solution, and preserved for surgical pathologic examination. One of the authors, a pathologist, reviewed the femoral section. Representative sections were taken from areas surrounding the screw and the autologous bony implant. These sections were submitted for decalcification and the tissue was then embedded in paraffin and stained with hematoxylin and eosin. Microscopic examination revealed early incorporation of the autologous bone plug with residual evidence of procedural fat necrosis. No evidence of foreign-body giant-cell reaction or inflammation was found (Fig 4).

DISCUSSION

ACL fixation methods have improved significantly over the past decade. Currently available methods include suture-post constructs, staples, soft-tissue washers, buttons, cross-pins, and interference screws. Although, many of these methods remain popular, the cannulated interference screw has emerged as one of the more widely used fixation methods. These screws gained popularity because they allowed for accurate and reliable fixation and facilitated rapid graft incorporation. Additionally, interference screw fixation fa-

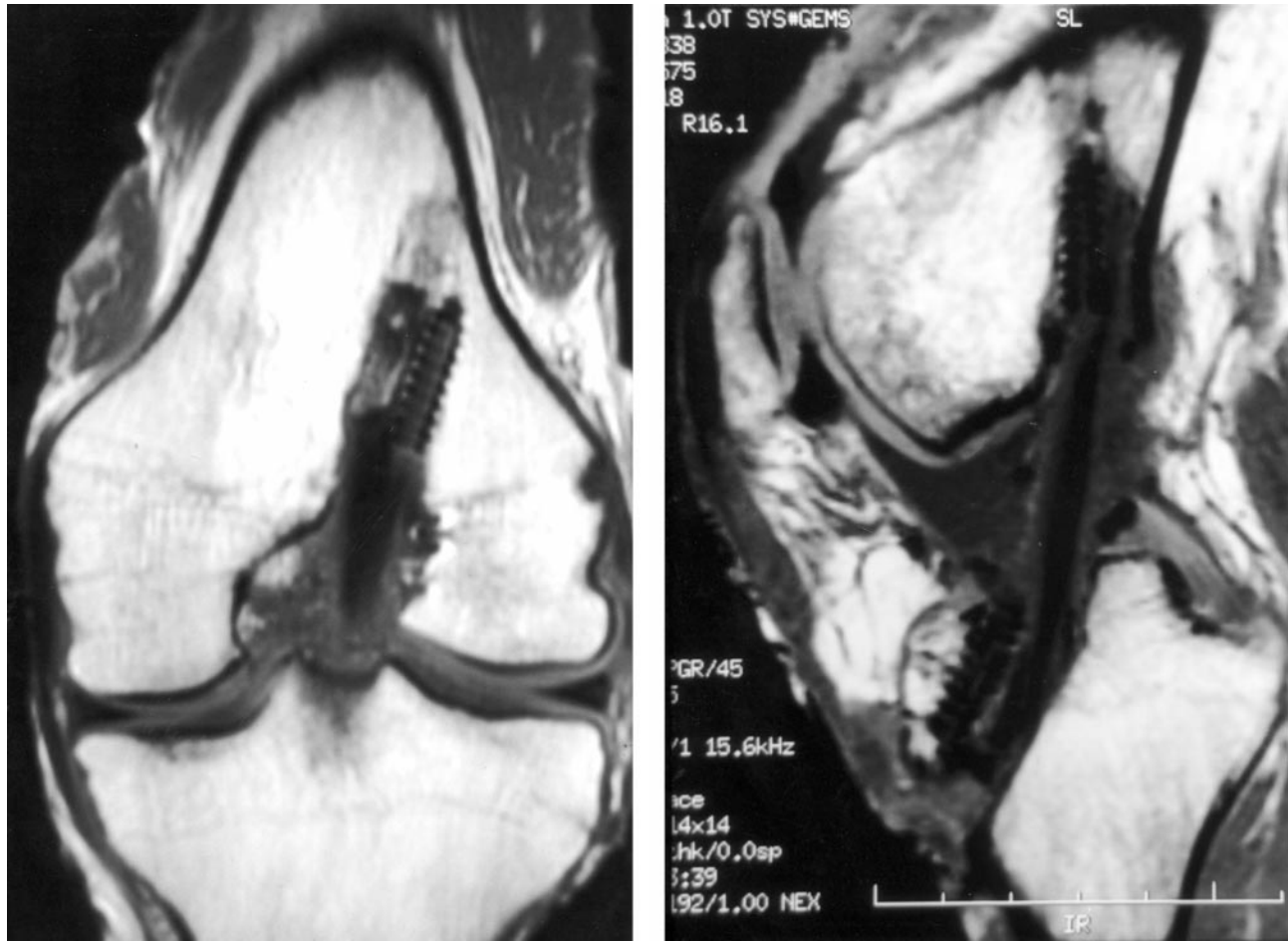


FIGURE 1. MRIs showed no evidence of lytic bone changes, tunnel widening, cyst formation, or fluid accumulation surrounding the screw. The screws appeared well seated between the autologous bone plug and the surrounding bone. Additionally, no screw resorption was observed after the 4 months of implantation.

Facilitates single-incision reconstruction techniques that reduce tourniquet time and surgical morbidity. Initially applied to patellar tendon grafts, interference screw use has expanded to include soft-tissue grafts.

Following the early biomechanical² and clinical^{3,4} successes with metallic interference screws, bioabsorbable interference screws were developed to address some of the problems associated with metallic screw fixation. These problems include imaging interference, cold intolerance, revision difficulty, and the possible need for hardware removal. However, concerns were raised about the orthopaedic use of bioabsorbable implants by several authors.⁵⁻¹⁰ Specifically, complications including foreign-body reaction, cyst formation, fluid collection, and sterile drainage were reported following the use of polyglycolic acid and polylactic acid (PLA) implants.

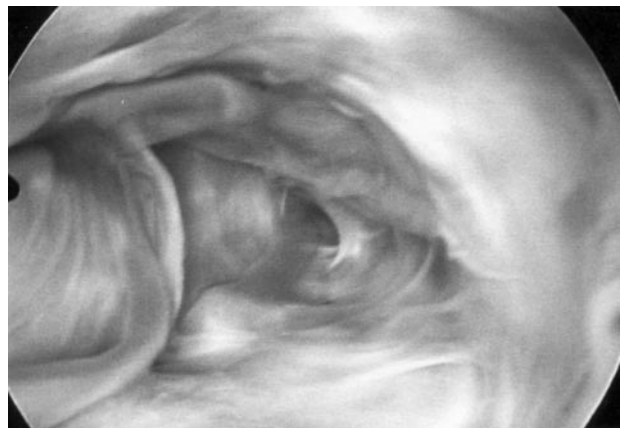


FIGURE 2. No inflammatory or foreign-body reaction was evident at the femoral tunnel site.

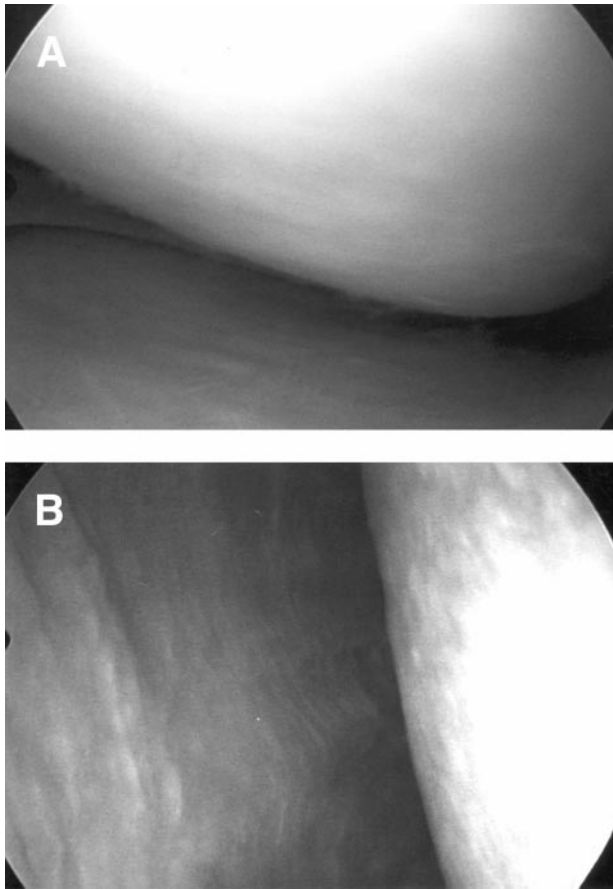


FIGURE 3. During the relook arthroscopy the (A) chondral and (B) synovial surfaces appeared normal with no evidence of chondral degeneration or synovitis, respectively.

A recent case report described an adverse reaction following ACL reconstruction with a poly-D, L-lactide (PDLLA) interference screw (Sysorb; Sulzer Orthopaedics, Baar, Switzerland).¹¹ The Sysorb screw is composed of a 50% levorotatory 50% dextrorotatory mixture. Eight months after reconstruction, the patient experienced swelling and pain over the anterior tibia. MRI analysis revealed an enlarged tibial tunnel that was filled with fluid and communicated with a pretibial subcutaneous cyst. After open excision of the pretibial cyst and debridement of the tibial tunnel, the patient's symptoms resolved.

The increased resorption rate associated with PDLLA when compared with poly-L lactic acid (PLLA) may account for the adverse reaction reported. PDLLA implants contain the stereoisomer dextrorotatory, which is known to affect the resorption rate. In one study, a sample of PDLLA showed an 88% decline in the initial molecular weight in 173 days whereas the PLLA sample took 479 days to reach this drop.¹²

Two studies^{13,14} have focused specifically on the use of PLLA BioScrew interference screws for ACL graft fixation. McGuire et al.¹³ followed-up 204 patients after ACL reconstruction for an average of 2.4 years. Patients were randomly assigned to either a BioScrew group (n = 103) or metal screw control group (n = 101). In every comparison between the groups, no statistically significant differences were found. No radiographic evidence of osteolytic changes or bone resorption around the BioScrew was found. Additionally, no complications related to loss of fixation, toxicity, allergenicity, or other evidence of osteolytic or inflammatory reactions were identified.

With the aid of serial MRI scans, Warden et al.¹⁴ followed-up 10 ACL patients who had received BioScrew graft fixation. MRI scans were obtained at 8, 16, and 24 months after implantation. At 2 years, no evidence of significant adverse reactions to the PLLA interference screws was identified. There was no cyst formation or drainage. Two patients developed an abnormal signal in the tibial tunnel, both of which resolved uneventfully.

Our observations following PLLA interference screw fixation were similar to those reported above. In this case, the use of the BioScrew did not elicit any intra-articular inflammatory reaction or adverse foreign-body reaction. Relook arthroscopy revealed a healthy viable graft that provided good resistance during an arthroscopic Lachman test. The chondral surfaces appeared normal and no evidence of synovitis was seen. Additionally, no histologic evidence of foreign-body reaction or inflammatory response was seen in the area surrounding the femoral screw.

There was no evidence of tunnel widening in the area of the screw. The presence of the BioScrew did not inhibit the incorporation of the autologous bone block into the surrounding native bone. The screws were well seated between the autologous bone plug and the surrounding bone. Histologic examination results showed evidence of early bone plug incorporation. Pullout failure occurred at the junction between the freeze clamps and graft at a load of 1,130 N. Because failure of the bone-screw interface was not observed at this load, we can assert that a fixation strength of at least twice that reported (550 N) in human cadaveric knee joints¹⁵ was obtained. We believe the pullout results can be interpreted as an indication that bone plug incorporation was occurring. It is tempting to assume that there would have been complete incorporation with time because there was an appropriate healing response.

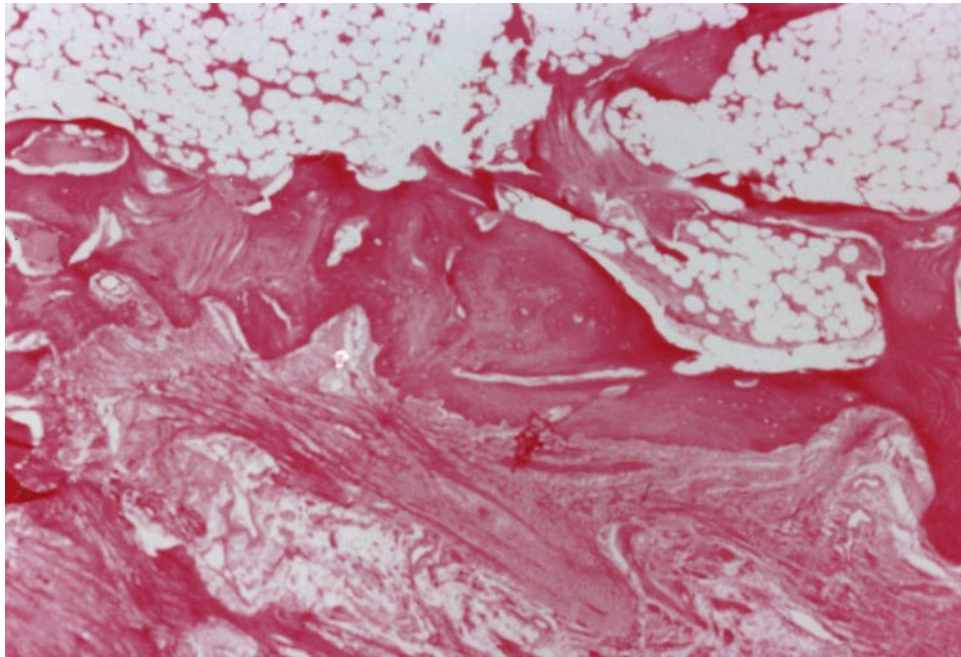


FIGURE 4. No histologic evidence of foreign-body reaction or inflammatory response was seen in the area surrounding the femoral screw.

CONCLUSIONS

Four months after autologous bone–patellar tendon–bone ACL reconstruction with BioScrew fixation, we found no evidence of tunnel widening, lytic bone changes, or inflammatory or foreign-body reaction. The BioScrew provided secure graft fixation and allowed bone plug incorporation. We believe this case suggests that the use of bioabsorbable PLLA interference screws is a safe and efficacious alternative to metallic screws.

Acknowledgment: The authors thank Stephen Hendricks, the Linvatec Corporation, and the Orthopedic Biomechanics Institute for their assistance during the development of this report.

REFERENCES

1. McGuire DA, Wolchok JC. Arthroscopic Lachman test: A new technique using anatomic references. *Arthroscopy* 1998;14:641-642.
2. Kurosaka M, Yoshiya S, Andrich JT. A biomechanical comparison of different surgical techniques of graft fixation in anterior cruciate ligament reconstruction. *Am J Sports Med* 1987;15:225-229.
3. Firer P. In vivo effectiveness of interference screw fixation for bone–ligament–bone anterior cruciate ligament reconstruction. Proceedings of the International Society of the Knee. *Am J Sports Med* 1991;19:538-539.
4. Bach BR, Jones GT, Sweet FA, Hager CA. Arthroscopy-assisted anterior cruciate ligament reconstruction using patellar tendon substitution. Two to four year follow-up. *Am J Sports Med* 1994;22:758-767.
5. Fraser RK, Cole WG. Osteolysis after biodegradable pin fixation of fractures in children. *J Bone Joint Surg Br* 1992;74:929-930.
6. Gerbert J. Effectiveness of absorbable fixation devices in Austin bunions. *J Am Podiatr Med Assoc* 1992;189-195.
7. Bostman O, Hirvensalo E, Makinen J, Rokkanen P. Foreign-body reactions to fracture fixation implants of biodegradable synthetic polymers. *J Bone Joint Surg Br* 1990;72:592-596.
8. Castelyn PP, Handelberg F, Haentjens P. Biodegradable rods versus Kirschner wire fixation of wrist fractures. *J Bone Joint Surgery Br* 1992;74:858-861.
9. Frokjaer J, Moller B. Biodegradable fixation of ankle fractures: Complications in a prospective study of 25 cases. *Acta Orthop Scand* 1992;63:434-436.
10. Tegnander A, Engebretsen L, Bergh K, Eide E, Holen K, Iverson O. Activation of the complement system and adverse effects of biodegradable pins of polylactic acid (Biofix) in osteochondritis dissecans. *Acta Orthop Scand* 1994;65:472-475.
11. Martinek V, Friederich NF. Tibial and pretibial cyst formation after anterior cruciate ligament reconstruction with bioabsorbable interference screw fixation. *Arthroscopy* 1999;15:317-320.
12. Migliaresi C, Fambri L, Cohn D. A study on the in vitro degradation of poly (lactic acid). *J Biomater Sci Polymer Ed* 1994;5:591-606.
13. McGuire DA, Barber FA, Elrod BF, Paulos LE. Bioabsorbable interference screws for graft fixation in anterior cruciate ligament reconstruction. *Arthroscopy* 1999;15:463-473.
14. Warden WH, Friedman R, Teresi LM, Jackson DW. Magnetic resonance imaging of bioabsorbable polylactic acid interference screws during the first 2 years after anterior cruciate ligament reconstruction. *Arthroscopy* 1999;15:474-480.
15. Caborn DN, Urban WP, Johnson DL, Nyland J, Pienkowski D. Biomechanical comparison between BioScrew and titanium alloy interference screws for bone–patellar tendon–bone graft fixation in anterior cruciate ligament reconstruction. *Arthroscopy* 1997;13:229-232.