

CHAPTER 50

Posterolateral Corner Injuries

David A. McGuire

Injuries to the posterolateral corner (PLC) of the knee, though infrequent, often present the most complex problems and can result in severe disability because of the relationship between rotatory instability, other ligamentous injury, and cartilage degeneration.^{29,38,85} The PLC is stabilized by a single functional unit known as the arcuate ligament complex.^{29,38} It is rare that injuries to the PLC occur in isolation, and indeed, they are often found in conjunction with posterior or anterior cruciate ligament (PCL, ACL) disruption.

Evolutionary anatomic development of the PLC has contributed significantly to its complex anatomy. Over time, developmental changes between the fibular head, biceps femoris muscle, and popliteus tendon have resulted in significantly intricate relationships. Particularly evident is the eventual descent over time of the fibular head from its initial articulation with the femur, which has contributed to speculation that its meniscus probably evolved into the popliteus attachment of the fibular styloid or the popliteus tendon. Anatomic comparisons with nonhuman mammalian species have identified similarities as well as variations in ligament attachments.

Fabricianni et al¹⁷ observed in their anatomic studies that the popliteus muscle continues into a complex aponeurosis consisting of popliteofibular, popliteocapsular (*popliteal aponeurosis*), and popliteomeniscal fibers (*popliteomeniscal fascicles*). Thereafter, it forms a strong tendon attached to the lateral femoral condyle with superior and inferior popliteomeniscal fibers. In these authors' comparative anatomy study of lower-order vertebrates, they presented evidence of tibial and fibular articulation with the femur, with each having its respective menisci. They also identified popliteus muscle fiber attachment on the head of the fibula posteriorly. The fibular head recedes in higher species and the corresponding meniscus disappears. In later stages of evolution, the popliteus muscle attaches to the femorofibular meniscus, even later it becomes the popliteus tendon, and the popliteus muscle develops a tendinous attachment to the fibular head (popliteofibular ligament [PFL]). The popliteus tendon, during these developments, maintained its association with the lateral meniscus (popliteal aponeurosis).

ANATOMY

Anatomic descriptions of the PLC have been inconsistent. Accordingly, there is confusion surrounding the anatomic structures and their function.^{83,87} The PFL has been defined by no less than five terms: popliteofibular fibers,¹⁷

the popliteus muscle with fibular head origin,⁸⁷ the short external lateral ligament,⁴⁶ the popliteofibular fascicles,⁷⁴ and the fibular origin of the popliteus.⁷⁶ This structure, notably absent in mid-20th century anatomy texts and orthopedic journals, has been rediscovered in the recent literature.⁵¹

The static stabilizers of the PLC include the lateral collateral ligament (LCL), PFL, arcuate ligament complex, fabellofibular ligament (FFL), and the posterolateral capsule. Dynamic stabilizing contributions⁶⁸ to the PLC include the biceps tendon, iliotibial tract (IT), and popliteus muscle-tendon complex. Injury to this complex can cause laxity that can result in posterolateral or anterolateral rotatory instability. The PLC controls anterolateral and posterolateral tibial rotation relative to the femur.^{22,50,73,79,91}

Seebacher et al⁶⁸ in 1982 described the knee lateral structures as being composed of three distinct layers (Fig. 50-1). The most superficial layer (layer I) consists of two parts, the superficial portion of the biceps and its expansion posteriorly and the IT, including its anterior expansion. The middle layer (layer II—an incomplete layer) contains the patellomeniscal ligament and, anteriorly, is composed of the quadriceps retinaculum but is incomplete posteriorly, where it consists of the two PFLs. The deepest (layer III) of the three layers forms the lateral part of the joint capsule. This layer is divided into superficial and deep laminae. The superficial (*lateral aponeuroses of the long and short heads, capsular arm of the short head of the biceps femoris*) lamina includes the LCL and terminates at the FFL. The deep lamina passes along the edge of the lateral meniscus, where a hiatus forms for the popliteus tendon and the coronary ligament, and terminates at the arcuate ligament complex.

The anatomy of the PLC is significantly variable. Seebacher et al⁶⁸ noted three anatomic variations in their study of 35 cadaver knees. The FFL independently reinforced the PLC portion of the capsule in 20%, the arcuate ligament complex reinforced it unaided in 13% of the knees, and both structures reinforced it in 67%. Sudasna and Harnsiriwattanagit⁷⁶ found variation in PLC structures in their dissection of 50 knees. They identified the fibular origin of the popliteus tendon (presently known as the PFL) in 98%, an FFL in 68%, and a thin, membranous arcuate ligament in 24%. In a study of 115 cadaver knees, Watanabe et al⁸⁷ used a classification scheme that identified the presence or absence of the “popliteus muscle” with origin from the fibular head (the PFL); seven anatomic variants were recognized, with variations of the arcuate ligament complex and FFL previously noted by Seebacher et al also being included. They found an LCL and a popliteus tendon in all knees and a PFL in 93%.

SECTION V Ligament Injuries

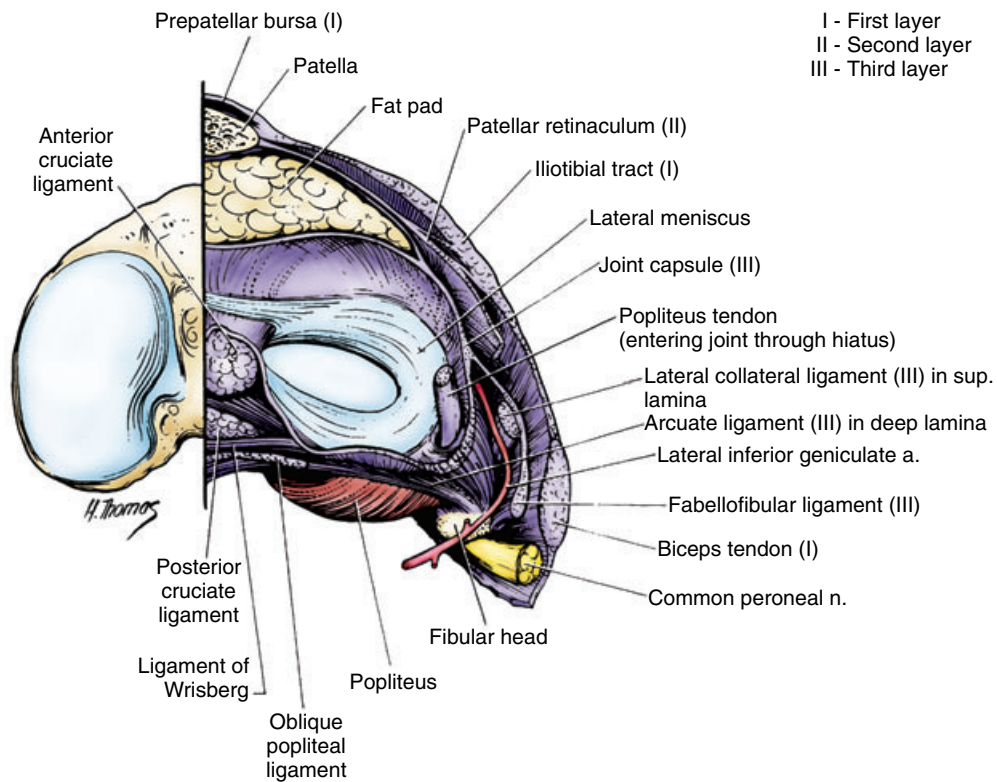


Figure 50-1. Coronal sectioned anatomy of the posterolateral corner of the knee. (From Seebacher JR, Inglis AE, Marshall JL, Warren RF: The structure of the posterolateral aspect of the knee. *J Bone Joint Surg Am* 64:536-541, 1982.)

BLOOD SUPPLY AND INNERVATION

The blood supply of the PLC is provided by the popliteal artery and its branches. Of the lateral superior genicular artery's three branches, the articular branch anastomoses with the ascending branch of the lateral inferior genicular artery, which runs anteriorly, deep to the LCL,^{78,84} and supplies the LCL and the lateral region of the knee. The middle genicular artery supplies the posterior capsular region,⁶⁷ with additional supply derived from the posterior tibial recurrent artery, which segregates into small branches supplying the tibial condyle, popliteus muscle, and the area superior to the fibular head.⁸⁴ Small branches off the popliteal artery also supply the posterior capsular region.⁸⁴

Injury to the PLC affects afferent signals to the central nervous system and knee kinematics. The PLC and the external portion of the lateral meniscus are supplied by the popliteal plexus, with aid from the terminal portions of the obturator nerve and the posterior articular nerve (a significant branch of the posterior tibial nerve).^{34,39} Proprioception in this knee region is facilitated by mechanoreceptors performing complex reflex arc roles. Golgi tendon organ–like endings and pacinian corpuscles serve a regulatory function for PLC structures in resisting external rotation and excessive varus force. Golgi endings, as slowly adapting high-threshold mechanoreceptors, are activated during extremes in knee range of motion (ROM) and when high stress is generated in ligaments. Pacinian corpuscles adapt and signal rapidly to changes in joint deceleration and acceleration.^{37,93}

By their location in and connection to ligaments, the capsule, and menisci, Ruffini endings provide static and dynamic mechanoreceptor input that signals the direction and amplitude of knee movement velocity, as well as changes in intra-articular pressure.^{37,93} The high-threshold free nerve endings that are ubiquitously present in most articular tissue are pain receptors that respond directly to inflammatory mediators and mechanical deformation.^{37,93}

BIOMECHANICAL STUDIES

Knowledge of the function and contribution to stability of individual PLC knee components has been derived largely from biomechanical studies. These studies provide a scientific basis for clinical assessment of a knee with PLC injury. Most research seeks to determine primary and combined function by measurement of knee motion in response to known forces with increasing anatomic defects in the knee.⁶²

In cadaver knee studies involving selective ligament sectioning, Nielsen et al⁵⁵⁻⁵⁸ illustrated the role of the PLC structures in opposing posterolateral rotational and varus forces. Collectively, the PLC and the LCL resist posterolateral rotation and varus displacement. The PLC plays the greater role in restricting posterolateral rotation, whereas the LCL plays a greater role in resisting varus displacement of the tibia.³⁷ Sectioning both the posterolateral part of the capsule and the LCL resulted in more posterolateral rotatory instability than did isolated resection of either

CHAPTER 50 Posterolateral Corner Injuries

structure.⁵⁸ The popliteus tendon resisted external tibial rotation between 20 and 130 degrees ROM, and it resisted varus displacement of the tibia from 0 to 90 degrees.⁵⁶ The PLC structures contributed secondary constraint to posterior translation. Isolated sectioning of the PCL did not affect external rotation or varus stability.^{55,57}

A study by Gollehon et al²³ expanded on the work of Nielson and colleagues by selective transection of the ACL, PCL, LCL, and the “popliteus-arcuate (deep) ligament complex” (DLC), which included the arcuate ligament complex and the FFL, the popliteus tendon, and the posterolateral part of the joint capsule.^{23,83} From 0 to 90 degrees ROM, the PCL was the principal structure resisting posterior translation, whereas the DLC and the LCL were the principal structures constraining posterolateral rotation and varus displacement. If either the DLC or the LCL were sectioned individually, there was no increase in posterior translation; however, their combined resection resulted in small increases in posterior translation throughout all ROM. A small varus displacement occurred at all knee angles in response to isolated LCL cutting, and when combined with resection of the DLC, varus displacement increased further in all ROM and was greatest at 30 degrees. With the addition of PCL sectioning, larger increases in varus displacement (from 15 to 19 degrees) occurred. When the DLC was sectioned, posterolateral rotation increased at 90 degrees, and when combined with LCL sectioning, posterolateral rotation increased at all angles, maximally at 30 degrees. When the PCL was also sectioned, additional increases in posterior translation and varus displacement occurred at all flexion angles, and posterolateral rotation increased at greater than 30 degrees of flexion. Isolated sectioning of the PCL did not affect posterolateral or varus displacement at any knee angle. When the ACL was sectioned along with the LCL and the DLC, tibial anterolateral rotation and anterior translation increased at 30 and 60 degrees of flexion. Isolated sectioning of the ACL or combined sectioning of the LCL and the DLC did not increase anterolateral rotation of the tibia.

In a study by Markolf et al,⁵⁰ sectioning of the PLC structures and subsequent posterolateral rotation or tibial varus produced increased force on the PCL at flexion between 45 and 90 degrees. Posterior tibial force and posterolateral rotation produced significantly increased stress on the PCL at all angles except full extension. With applied anterolateral rotation, there was no effect on the PCL. However, stress increased on the ACL from 0 to 20 degrees of flexion.

Noyes et al⁶³ quantified increases in abnormal posterior subluxation of the tibial plateau subsequent to ligament sectioning and specified loading conditions. Transection of both the PCL and PLC structures increased posterior subluxation of both the lateral and medial tibial plateau at 30 and 90 degrees of flexion. Subsequent to cutting the PLC structures, posterior translation of the lateral tibial plateau increased at 30 but not at 90 degrees of flexion.

LaPrade et al⁴⁴ measured the stress in ACL grafts in cadaver knees in which the PLC structures had been selectively cut. Graft force increased with varus loading, and it increased further with coupled varus and posterolateral rotation at 0 and 30 degrees of flexion.

In their study of articular contact pressure with the use of pressure-sensitive film, Skyhar et al⁷² reported that combined sectioning of the PCL and PLC produced significantly more patellofemoral joint contact pressure than did isolated sectioning of the PCL ($p < .05$). Their cadaver knee model simulated non-weightbearing, resistive extension of the knee.

CLINICAL RELEVANCE

Isolated Ligament Injuries

Although PLC injury may be isolated or occur as part of a multiligament injury, isolated PLC injury is rare. In their report of 735 knees treated for ligament injuries, DeLee et al¹⁶ identified only 12 (1.6%) that had acute isolated posterolateral rotatory instability. The most common mechanisms of injury to the PLC of the knee include athletic trauma, falls, and motor vehicle accidents.^{3,16,21,24,41,60,81} If posterolateral force is directed to the proximal part of the tibia with the knee at or near full extension, an isolated PLC injury can result.^{16,29} Knee hyperextension and a varus force combined can disrupt the PLC structures.^{3,4,21} When isolated PLC injury occurs, the following conditions are typically found:

1. Posterior tibial translation = minimum (same as the reference knee)
2. External rotation at 30 degrees of knee flexion = maximum
3. Stable examination at 90 degrees

An isolated complete injury of the PLC results in maximally increased varus and external rotation at 30 degrees of flexion if the PCL is intact. At low knee flexion angles, only 10% to 15% of the PCL's fibers are taut, and it is accordingly unable to significantly resist such force.^{14,15} In contrast, the fibers of an intact PCL are tight at 90 degrees and are able to exert an effective secondary restraint against posterolateral rotatory torque, or a varus force, and to exert a primary restraint against posterior translation.^{25,50,66}

Signs of isolated PLC injury differ significantly from those associated with isolated LCL injury. Isolated LCL injury is manifested as mildly increased varus displacement at 0 degrees but as maximal displacement at 30 degrees of knee flexion. It is best assessed with adduction stress testing at 30 degrees.

Isolated tears of the PCL produce increases in posterior translation of the tibia that correlate positively with knee flexion. However, there is no correlation with posterolateral or anterolateral rotatory instability or varus displacement. The posterior drawer test at 90 degrees is the most accurate means of diagnosing such an injury.¹⁴ Accordingly, an isolated PCL injury will have the following findings:

1. Abnormal posterior laxity
2. No abnormal varus
3. Dial test result for external rotation of the tibia on the femur less than 5 degrees as compared with the uninvolved side tested with the knee at 30 and 90 degrees of flexion

SECTION V Ligament Injuries

Posterolateral Corner–Posterior Cruciate Ligament Injury Combination

PLC impairment is more frequently associated with multiple ligament injuries, and posterolateral rotatory instability is notably a common condition that occurs secondary to PCL damage. Injury mechanisms include those contributing to isolated PLC injury, hyperextension combined with posterolateral rotatory force, a severe tibial posterolateral rotation force, or a severe varus force.^{4,12,45,81} A combined injury may also occur when a flexed knee receives a posterior force on the tibia while externally rotated. In this situation, PCL tension is significantly decreased in comparison to the tension present during neutral tibial rotation because the PLC structures are recruited to resist the applied force.⁸⁶ A frank knee dislocation can also produce severe injury to the PLC.^{24,81,90}

When a complete PLC injury is combined with a PCL injury, the primary and secondary restraining effects of the PCL are lost at high knee flexion angles. Consequently, there is increased posterolateral rotatory instability, varus displacement, and posterior translation at *all* knee angles.⁸³ When isolated or combined PLC injury is suspected, stress tests for increased varus displacement and posterolateral rotatory instability should be performed at 30 and 90 degrees and compared with the results in the uninjured knee.⁸³ An injury to the PLC structures combined with a PCL injury will typically be manifested as follows:

1. Abnormal posterior laxity greater than 20 to 25 mm; tibial step-off is absent and negative
2. Abnormal varus displacement at 30 degrees
3. Abnormal external rotation thigh-foot angle of greater than 10 to 15 degrees in comparison to the normal lower extremity tested at 30 and 90 degrees

Posterolateral Corner–Anterior Cruciate Ligament Injury Combination

Though less well recognized, combined ACL and PLC injury can occur. Collectively, this multiple injury results in increased primary anterior and posterior translation, primary varus laxity, coupled posterolateral rotatory instability, and anterolateral rotatory instability.^{82,91} There is disagreement whether the external rotation test at 30 degrees is a reliable method for identifying combined ACL and PLC injury. Although anterolateral rotatory instability is commonly associated with ACL insufficiency, identifying which cases are combined PLC and ACL injuries may require intraoperative assessment. When PLC involvement is suspected, post-ACL reconstruction flexion-rotation drawer and dial tests can verify PLC insufficiency requiring surgical intervention. The data support the clinical observation that cruciate ligament grafts are at risk for failure in knees with untreated posterolateral and anterolateral rotatory instability.²⁶ Consequently, intraoperative assessment of PLC insufficiency may easily and

perhaps should routinely be conducted immediately after postoperative ACL and PCL reconstruction.

DIAGNOSIS AND PHYSICAL EXAMINATION

Because the majority of all PLC injuries occur in conjunction with other ligamentous disruption, they may be overlooked during an initial knee examination.^{12,59,75} Patients with PLC injuries typically have diffuse tenderness, ecchymosis, edema, induration and tenderness over the PLC area, and localized tenderness over the fibular head.^{3,16} Localized point tenderness at the joint line may indicate a Segond fracture.^{45,69,70}

Examination is carried out to ascertain the functional integrity of specific structures, and comparison is made with the uninjured knee. Lesions of the PLC structures are often classified as grade I, II, or III sprains, depending on whether there is minimal, partial, or complete tearing of the ligament.^{2,38,43,45} Grade I injuries are not associated with abnormal joint motion, grade II injuries are associated with slight to moderate joint motion, and grade III injuries are usually associated with markedly abnormal joint motion.²

A posterior drawer test should be performed at 30 and 90 degrees.³² After applying gentle posterolateral rotational force, assess the amount of posterolateral rotation and compare it with the contralateral normal knee. Note that some normal laxity is seen in patients with physiological genu recurvatum. If posterior translation is normal at 90 degrees but is slightly increased at 30 degrees, PLC injury is likely. Not all patients with PCL tears have a positive posterior drawer test on physical examination.²⁸ Although the PCL is commonly evaluated by performing the posterior drawer test at 90 degrees,^{23,25,27,59} it can also be assessed by other methods, including the dynamic posterior shift test,¹⁵ the quadriceps active test, the posterior sag sign, the prone posterior drawer test, and the reverse pivot-shift test.³⁵ The reverse pivot-shift test has the largest variability of all motion tests (with positive results occurring in 35% of normal knees examined under anesthesia).¹¹ The knee is flexed to 45 degrees, the foot is externally rotated, and the knee is then extended.

During assessment of patients with known PCL tears, diagnosis of potential injury to the PLC should be undertaken with the patient in a supine position.¹³ The posterolateral external rotation test⁴⁵ is conducted at 30 and 90 degrees, with a combined posterior and external rotation force being applied while palpating for posterolateral subluxation of the tibia. If subluxation occurs at 30 degrees but not at 90 degrees, an isolated injury of the PLC is indicated. If subluxation occurs at both angles, a combined PLC and PCL injury is suggested.

The dial (tibial external rotation) test assesses increased external rotation and may be performed with the patient supine or prone, although it may be easier to visualize side-to-side differences in the latter position.^{1,83} The test should be performed at both 30 and 90 degrees because increased external rotation at 30 degrees but not at 90

CHAPTER 50 Posterolateral Corner Injuries

degrees indicates an isolated injury to the PLC whereas increased external rotation at both angles suggests injury to both the PCL and the PLC. Differences between the results of the 30- and 90-degree dial tests may be so slight that they are not visually detectable. If external rotation of the injured tibia exceeds 10 degrees in a side-to-side comparison with the noninjured tibia, a PLC injury is suggested.⁵ The external rotation recurvatum test^{29,32} is used to diagnose posterolateral rotatory instability but is usually indicative of a combined injury with the PCL. The test is performed by lifting the patient's extended legs by the great toes and noting any relative difference in hyperextension, tibial external rotation, and varus.

Assessment of the ACL is commonly undertaken with the Lachman test.⁸⁰ A combined ACL and PLC injury should be suspected in severe injuries or if the ACL insufficiency is chronic. Either of these circumstances in the presence of a grade II to III Lachman test *combined with* a grade II to III flexion-rotation drawer test is indicative of a combined injury. It should also be suspected if the patient is undergoing a revision ACL reconstruction and there were no signs of injury, noncompliance with physical therapy, or incorrect surgical methodology.

Patients with PLC injuries usually, but not always, demonstrate varus alignment while standing and may learn to adapt to their instability with a flexed knee gait. This abnormal gait pattern is characterized by a varus thrust, or a hyperextension varus thrust may develop during their stance phase.^{60,83}

DIAGNOSTIC IMAGING

Standard anterior-posterior radiographs of a knee with posterolateral injury may show abnormal widening of the lateral joint space or a Segond fracture.^{16,41,60} Avulsion of the lateral aspect of the capsule from the tibial plateau (Segond fracture—lateral capsular sign) is typically indicative of an ACL lesion. However, an isolated PLC injury may be seen as avulsion of metaphyseal bone from the tibia.^{16,68} Although chronic PLC injuries correlate positively with radiographs demonstrating osteoarthritic changes in the lateral or medial compartment or with patellofemoral arthritis,^{6,29} these data have limited use in primary PLC diagnosis.

Magnetic resonance imaging (MRI) is useful in diagnosing PLC injury, particularly in severely traumatized, acutely injured knees wherein a complete and accurate clinical diagnosis is not possible.^{54,65,77,88} Coronal oblique T2-weighted MRI has been demonstrated in cadaveric and clinical studies to provide improved visualization of PLC structures when compared with standard coronal or sagittal views.⁹² In a prospective clinical study, LaPrade et al⁴² used a thin-sliced coronal oblique T1-weighted protocol designed to include the entire fibular head and styloid process in their comparison of seven uninjured knees to 20 patients with grade III PLC injuries. They were able to accurately identify PLC structures individually and determine the chronic or acute nature of the lesions with this protocol.

TREATMENT

Nonoperative

Kannus³⁸ monitored 23 patients with nonoperated grade II and III sprains of the PLC. Eleven patients with grade II sprains had excellent or good result, 9 were asymptomatic, and all had residual laxity. Twelve patients with grade III sprains all had fair to poor results on their standardized scores, and 6 had post-traumatic arthritis.

Surgical Reconstruction

Reconstruction techniques for the PLC include partial and complete tendon transfers, among which are femoral bone block advancement of the arcuate ligament complex, lateral gastrocnemius muscle advancement, biceps tendon tenodesis, and hamstring or patellar tendon reconstruction of the LCL from the fibular head to the isometric point of the femur.^{8,31,47,60,61,85} Individual ligament replacement techniques for PLC insufficiency include an LCL anatomic reconstruction using the central segment of the biceps femoris tendon (Fig. 50–2),⁷ reconstruction of the tibial attachment of the popliteus tendon and the PFL with a split patellar tendon graft (an Achilles tendon may also

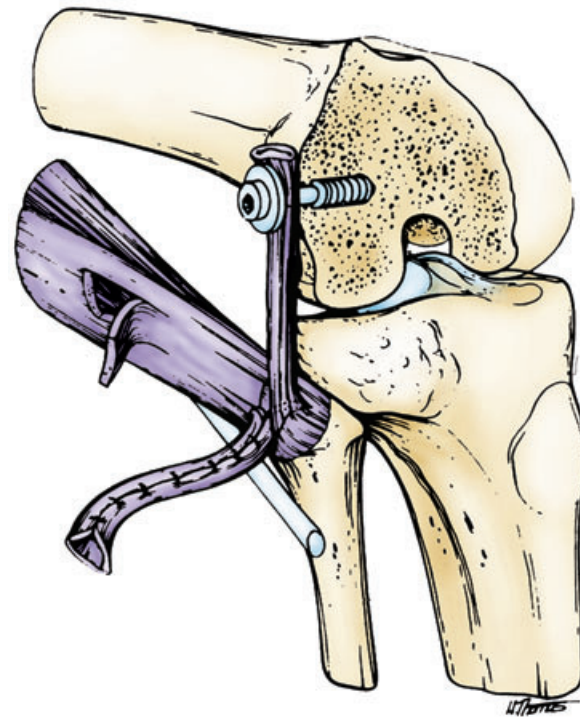


Figure 50–2. View of lateral collateral ligament reconstruction with a central strip of biceps tendon. (From Bowen MK, Warren RF, Cooper DE: Posterior cruciate ligament and related injuries. In Insall J [ed]: *Surgery of the Knee*, 2nd ed. New York, Churchill Livingstone, 1993.)

SECTION V Ligament Injuries

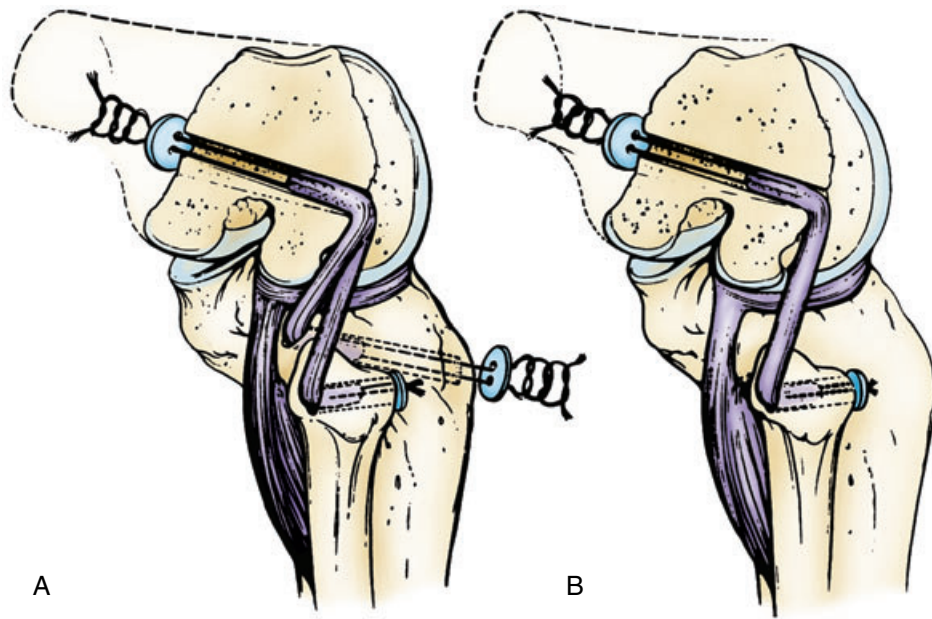


Figure 50-3. A, Reconstruction of the popliteus-tibial attachment and popliteofibular ligament with a split patellar ligament graft. Subsequent to proximal femoral tunnel placement, the graft is split and one end placed in the tibial tunnel and the other in the fibular tunnel. B, Reconstruction of the popliteofibular ligament with a patellar ligament graft. (From Veltri DM, Warren RF: Posterolateral instability of the knee. Instr Course Lect 44:441-453, 1995.)

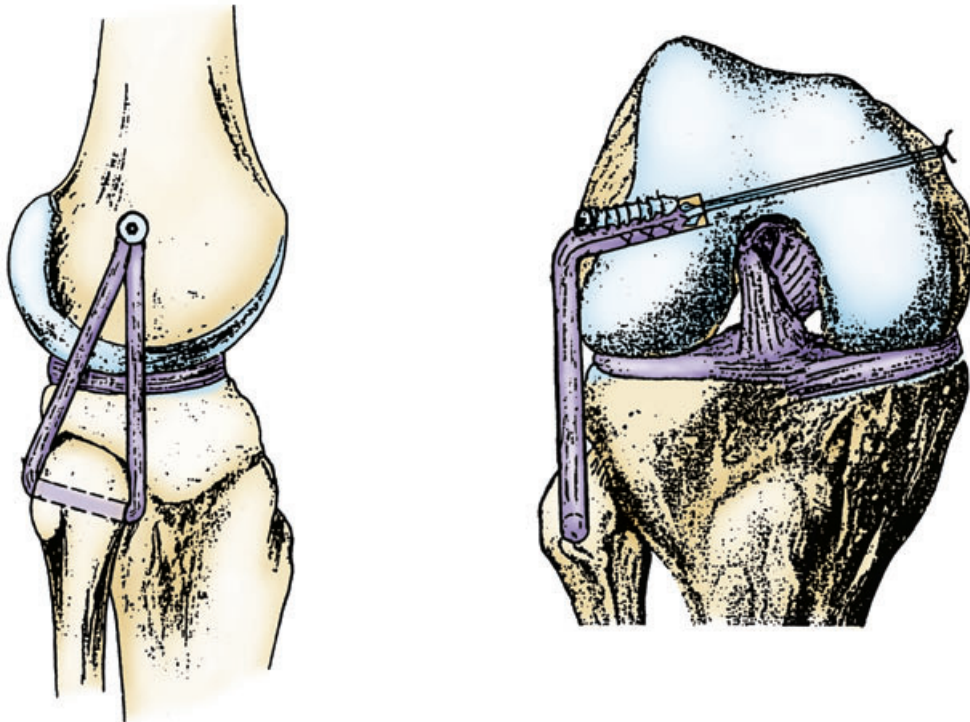


Figure 50-4. Illustration of a lateral collateral ligament and popliteofibular ligament reconstruction with a free semitendinosus tendon graft. (From Fanelli GC, Larson RV, Practical management of posterolateral instability of the knee. Arthroscopy 18(2 Suppl 1):1-8, 2002.)

be used), or isolated reconstruction of the PFL with a graft (Fig. 50-3).⁸³

Other reconstruction examples include LCL/PFL substitution with the semitendinosus (Fig. 50-4)²⁰ and split Achilles (Fig. 50-5),⁴⁸ PFL substitution with the semitendinosus without significant varus instability (Fig. 50-6),²⁰ split biceps tendon transfer (biceps femoris tendon tenodesis),¹⁸ rerouted biceps tendon,⁴⁰ and fibular head oblique osteotomy.⁶⁴

Study Results

In 21 patients with combined PLC and cruciate ligament injuries, Noyes and Barber-Westin⁶¹ reported that 13 (61.9%) were fully functional, 6 (28.6%) were partially functional, and 2 (9.5%) were nonfunctional. They used a modified Hughston and Jacobson³⁰ technique in which the tissue is advanced with the knee in 30 degrees of flexion rather than at 90 degrees. In another combined

CHAPTER 50 Posterolateral Corner Injuries

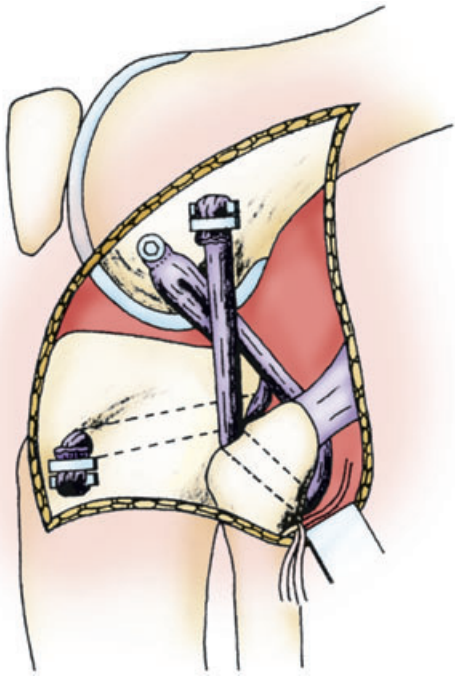


Figure 50-5. Posterolateral reconstruction with a split Achilles tendon allograft. A bone plug is placed in the anteroinferior side tunnel of the femur and secured with a cannulated interference screw. The 6-mm-wide and 7-mm-wide sides of the graft are secured by staples on the femur and tibia, respectively. (From Lee MC, Park YK, Lee SH, et al: Posterolateral reconstruction using split Achilles tendon allograft. *Arthroscopy* 19:1043-1049, 2003.)

PLC and cruciate ligament series involving 39 patients, Clancy and Sutherland¹⁰ performed a tenodesis of the biceps femoris tendon to the lateral femoral epicondyle. They reported that 77% had no restrictions in activities of daily living and 54% were able to return to their previous level of sports competition. In a combined PLC-PCL study by Fanelli et al,¹⁹ all 21 patients had either correction or overcorrection of their posterolateral instability as measured by the tibial external rotation test.

Jacob and Warner³⁶ suggested that recession of the popliteus tendon and LCL into the lateral femoral condyle can restore tension yet maintain the anatomic attachment sites. This procedure would be appropriate in cases of mild attenuation when the popliteus musculotendinous junction and the PFL are intact. A study by Albright and Brown¹ reported the results of a sling procedure used to approximate reconstruction of the popliteus tendon. This procedure eliminated the reverse pivot shift, hyperextension, and varus laxity in 26 (87%) of the study's 30 patients.

Using a rerouted biceps tendon technique in patients with isolated rotatory instability, Kim et al⁴⁰ reported that external rotation was normal in 15 (71%) of the 21 patients at follow-up and loss of correction of more than 5 degrees was found in 3 patients at an average of 1 year postoperatively. Patients were immobilized at 30 degrees for 6 weeks, with partial weightbearing permitted thereafter with passive and active ROM.

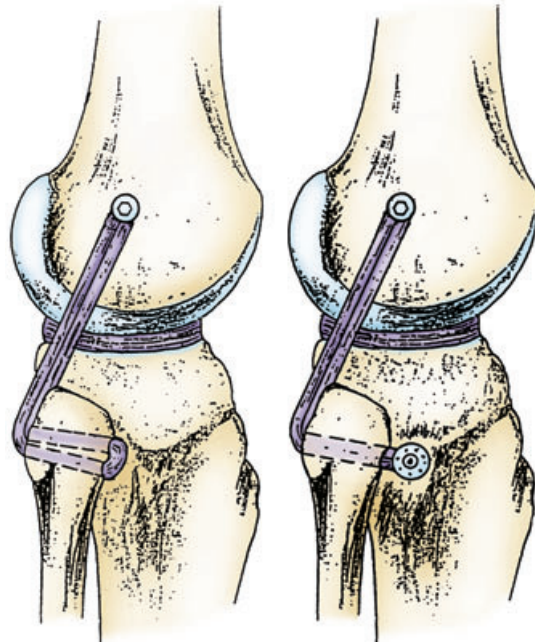


Figure 50-6. Illustration of a semitendinosus free graft used to reconstruct posterolateral corner instability without varus instability and without (A) or with (B) tibiofibular joint instability. (From Fanelli GC, Larson RV: Practical management of posterolateral instability of the knee. *Arthroscopy* 18(2 Suppl 1):1-8, 2002.)

Operative Technique

The reconstruction techniques described are all complex and require the rearrangement of normal structures. No matter how carefully done, there is a penalty for moving normal structures to new locations. In an effort to simplify the reconstruction and minimize the associated morbidity of the procedure, we have developed and currently use the following techniques.

ANTEROLATERAL LATERAL AUGMENTATION DESIGNED TO ELIMINATE ANTEROLATERAL ROTATORY INSTABILITY

To minimize donor site morbidity, a semitendinosus or other suitable allograft may be used. However, if allograft tissue is not available, autologous tissue may be substituted. A lateral incision is made through subcutaneous tissue from the lateral femoral epicondyle to Gerdy's tubercle. The fascia lata is divided longitudinally. Gerdy's tubercle is identified along with the site just posterior to the insertion of the LCL on the femur (Fig. 50-7). Slot-eyed Beath pins are then placed in these positions (Fig. 50-8).

Initially, the pins are drilled or tapped a short distance into the bone, and a suitably strong suture material is stretched between these two pins (Fig. 50-9). The knee is then put through full ROM. Tension changes in the suture

SECTION V Ligament Injuries

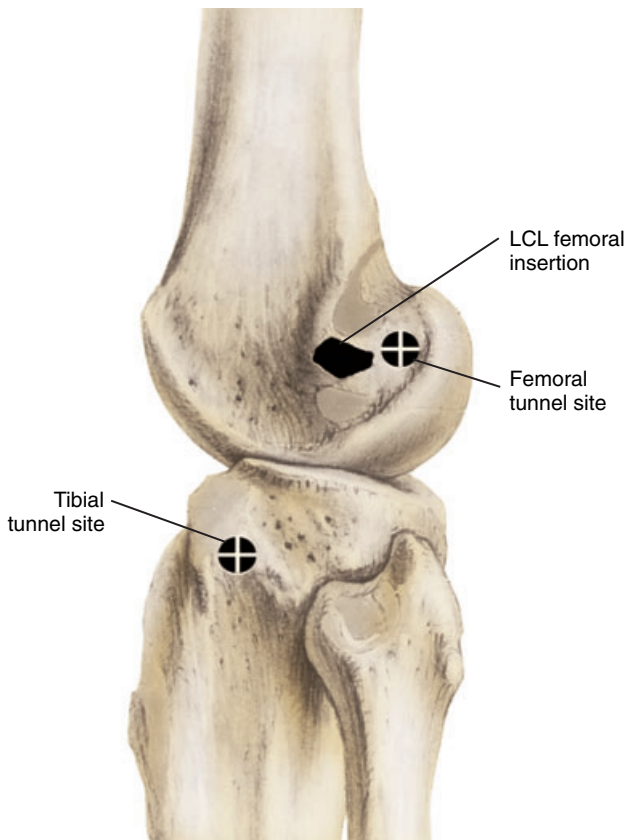


Figure 50-7. The tibial tunnel site is located just anterior to Gerdy's tubercle, and the femoral tunnel site is located just posterior to the insertion of the lateral collateral ligament (LCL) on the femur.

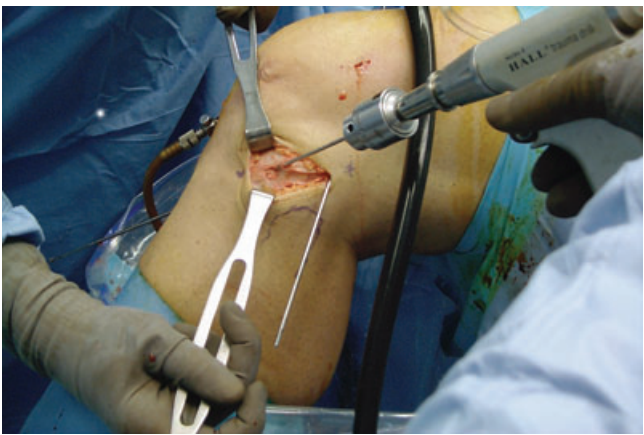


Figure 50-8. Insertion of the slot-eyed Beath pins into the approximated position.

so placed should be less than 2 mm. This is a simple, but useful approximation of isometry. If the tension in the suture is inadequate or the suture breaks, which is indicative of a nonisometric position, the pins are reinserted at a more suitable site until satisfactory isometry is established. The work of Sidles et al⁷¹ established that no truly isometric positions exist laterally and extra-articularly.

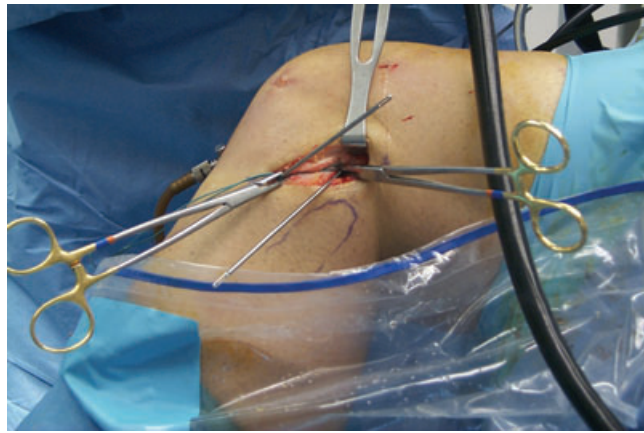


Figure 50-9. Beath pins are wrapped with suture material to determine site-selected isometry of 2-mm or less excursion during range-of-motion testing.

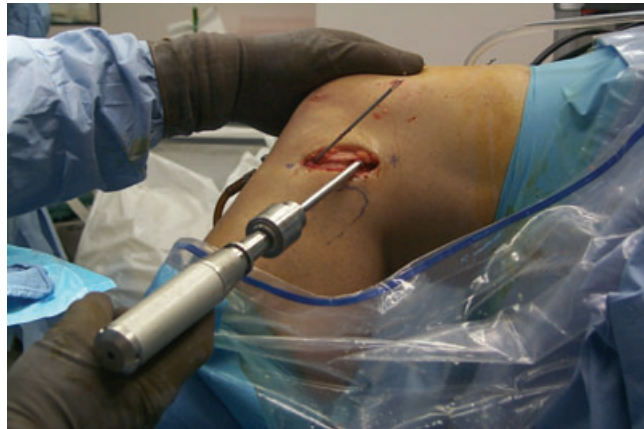

Figure 50-10. Femoral tunnel being overdrilled with a 7-mm reamer to a depth of 25 mm.

However, this method produces a useful approximation that will protect the ACL graft in these instances of severe anterolateral rotatory instability.

Once this relatively isometric position is established, the femoral pin is drilled through the femoral cortex with its exit directed medially and sufficiently proximal to avoid the femoral tunnel of the previously reconstructed ACL. The tibial pin is advanced distally and medially to avoid the tibial tunnel and then exits the skin. Once adequate pin position is achieved, a 7-mm cannulated reamer is advanced over the Beath pins, and both tunnels are drilled to a depth of 25 mm (Fig. 50-10). A wire suture is placed at both ends of the graft, which is then advanced into the tunnels with the aid of the slot-eyed Beath pins (Fig. 50-11). With the knee held in 20 degrees of flexion, the graft is tensioned to approximately 5 kg, and direct tendon-to-bone fixation is accomplished with 7 × 25-mm bioabsorbable interference screws placed over a guide wire (Fig. 50-12). Stability is then checked (Fig. 50-13). The pivot-shift phenomenon should be completely eliminated. The wound is then closed with subcuticular absorbable sutures. Use of this relatively simple extra-articular recon-

CHAPTER 50 Posterolateral Corner Injuries

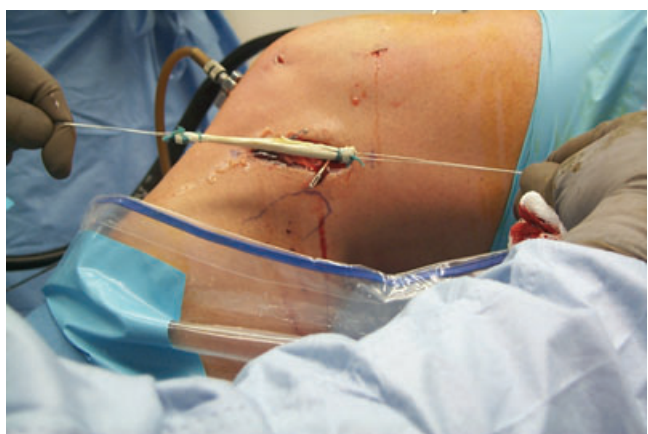

Figure 50-11. Graft shown in preparation for insertion. Note the slot of each Beath pin is positioned to receive the graft wire before placement of the graft ends into their respective tunnels.

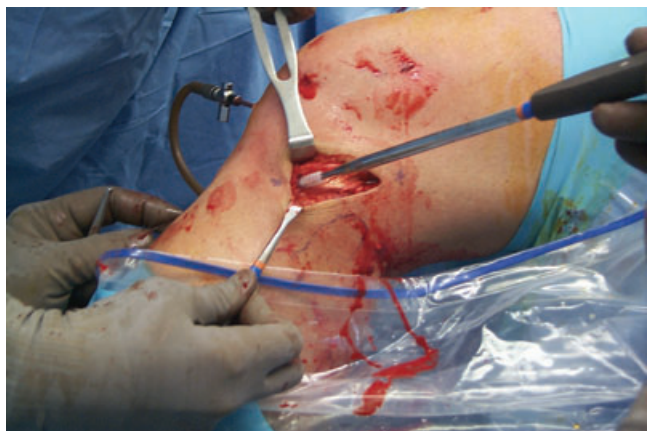

Figure 50-12. Insertion of a 7 × 25-mm headless cannulated bioabsorbable interference screw for direct interference fixation of the tibial side of the graft. Another identical screw is used for femoral side fixation.

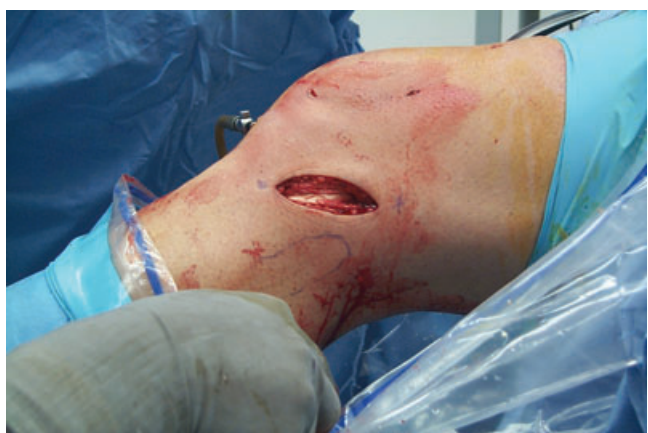

Figure 50-13. Graft secured while awaiting flexion-rotation drawer testing and wound closure with subcuticular absorbable suture.

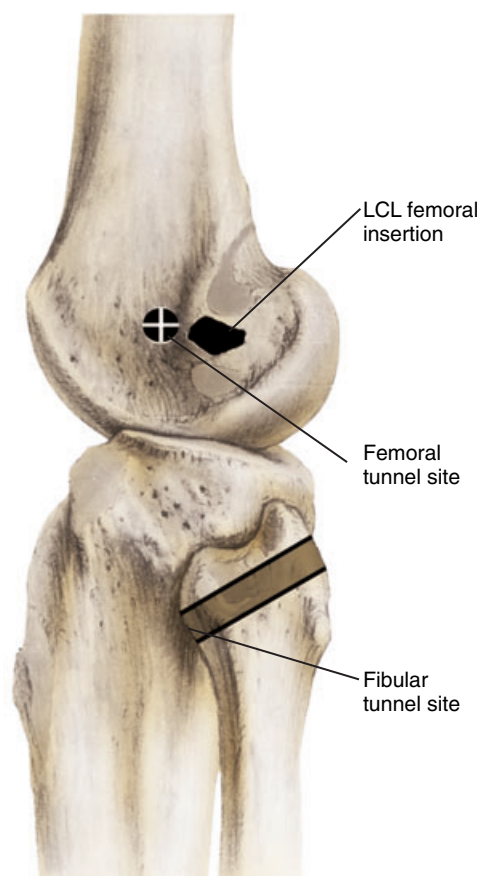


Figure 50-14. The proximal tunnel site is located just anterior to the insertion of the lateral collateral ligament (LCL). The distal tunnel located in the fibular head is drilled obliquely, angling from posterior proximal on the fibular head to anterior distal, and then exits through the skin anteriorly.

struction has significantly improved our success rate in these severely unstable knees.⁸⁹

POSTEROLATERAL LATERAL AUGMENTATION DESIGNED TO ELIMINATE POSTEROLATERAL ROTATORY INSTABILITY

The posterolateral reconstructive surgical technique mirrors that of the anterolateral reconstruction. The only significant difference is the location of the distal and proximal tunnels. To establish the proximal tunnel, a site just anterior to the LCL is identified (Fig. 50-14), and a guide wire is placed in this position. The guide wire and subsequent tunnel should be oriented in a proximal medial direction so that it avoids the femoral tunnel of an ACL reconstruction (Fig. 50-15). The foot is then internally rotated, thereby exposing the head of the fibula. To establish the distal tunnel, a guide wire is drilled obliquely, angling from posterior proximal on the fibular head to anterior distal, and then exits through the skin anteriorly. Like the anterolateral reconstruction, isometry is evaluated with a suture. The final tunnels are drilled, and with

SECTION V Ligament Injuries

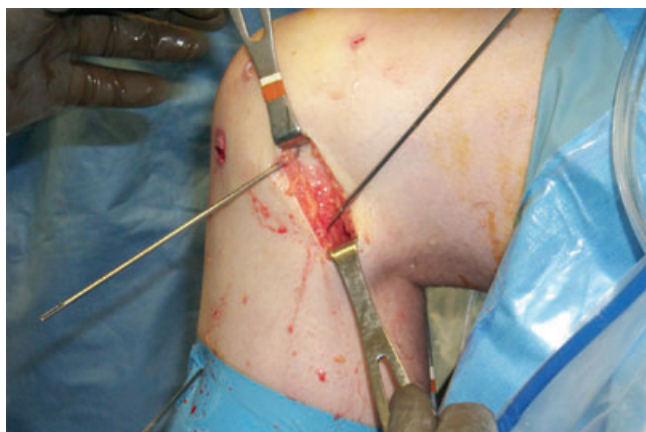

Figure 50-15. Insertion of the slot-eyed Beath pins into their respective approximated positions.

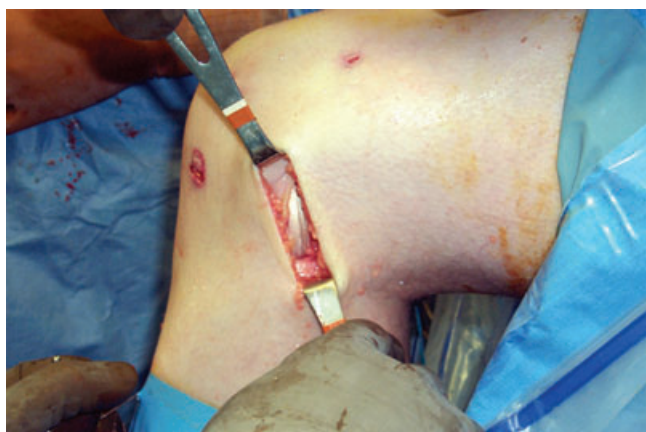

Figure 50-16. Graft secured while awaiting the dial test and wound closure with subcuticular absorbable suture.

the knee in approximately 90 degrees of flexion, direct tendon-to-bone fixation is accomplished with bioabsorbable interference screws. Under tension, the femoral insertion is fixed first, followed by the fibular insertion (Fig. 50-16).⁵³

Rehabilitation

The postoperative program is similar to the program after an isolated ACL reconstruction. Postoperative pain may be greater after lateral reconstruction, and therefore proper pain management is crucial so that early rehabilitation can be initiated. Rehabilitation emphasizes ROM, quadriceps strengthening, and patellofemoral joint protection. Patients are allowed weightbearing as tolerated, with the majority returning to full weightbearing by the seventh postoperative day. The postoperative ROM protocol includes continuous passive motion and heel slides, with the goal of full ROM by the sixth postoperative week.

Cold therapy is used to reduce postoperative pain and swelling.

The postoperative exercise program emphasizes quadriceps strengthening and avoids all flexion and extension against resistance. Immediately after surgery all patients begin a strengthening program that consists initially of straight-leg raises. Patients progress to nonimpact sliding/gliding exercises as tolerated. Specifically, patients begin a program consisting of swimming, Nordic track, and stationary bicycling usually beginning by the end of the second postoperative week. If any activity produces pain, patients are instructed to discontinue or limit the extent of that exercise.

DISCUSSION

PLC instability can be anterior, posterior, or both. The instability can be isolated or exist in conjunction with other ligamentous injuries. The possibility of PLC injury should be considered when examining any injured knee for ligamentous injury. However, PLC instability may be best confirmed intraoperatively after completion of ACL or PCL reconstruction. This injury pattern is easily diagnosed, and a MRI study may be helpful in borderline cases.

It has been suggested that all grade I and most moderate grade II injuries of the PLC structures can be treated nonoperatively, but residual laxity may remain, especially in knees with grade II injuries.¹³ Mild grade II injuries can probably and occasionally be treated nonoperatively; however, differentiation between grade I and II injury is often complicated by concomitant multiple ligament injuries. Additionally, a poorly reconstructed ACL can mimic injury to the PLC. If the tibial tunnel is placed so posterior that the position of the ACL graft is too vertically oriented, the resulting rotational instability can mimic a PLC injury.

Acute grade III isolated or combined injury of the PLC is best treated early, by direct repair if possible, or else by augmentation or reconstruction of all injured ligaments. Chronic PLC injury, whether isolated or combined, is probably best treated by reconstruction of the PLC along with reconstruction of any coexisting cruciate ligament injury.

Clinical outcomes of PCL reconstruction have not been as successful as those achieved after ACL reconstruction.^{9,21,33,49,60,89} The commonly associated PLC injury, if left unattended in PCL disruptions, may contribute to unsuccessful PCL reconstruction. However, there seems to be a greater percentage of posterolateral rotatory instability among PCL-deficient patients than anterolateral rotatory instability among ACL-deficient patients. This may be due to a higher percentage of severe trauma associated with the PCL group. Biomechanical data support the clinical observation that cruciate ligament grafts are at risk for failure in knees with untreated anterolateral or posterolateral rotatory instability.²⁶ Failure to diagnose and treat a PLC injury in a patient who has a known tear of the ACL or PCL can result in failure of the reconstructed cruciate ligament.

CHAPTER 50 Posterolateral Corner Injuries

References

- Albright JP, Brown AW: Management of chronic posterolateral rotatory instability of the knee: Surgical technique for the posterolateral corner sling procedure. *Instr Course Lect* 47:369-378, 1998.
- American Medical Association, Committee on the Medical Aspects of Sports: Standard nomenclature of athletic injuries. Prepared by the Subcommittee on Classification of Sports Injuries. Chicago, American Medical Association, 1966.
- Baker CL Jr, Norwood LA, Hughston JC: Acute posterolateral rotatory instability of the knee. *J Bone Joint Surg Am* 65:614-618, 1983.
- Baker CL Jr, Norwood LA, Hughston JC: Acute combined posterior cruciate and posterolateral instability of the knee. *Am J Sports Med* 12:204-208, 1984.
- Bleday RM, Fanelli GC, Giannotti BF, et al: Instrumented measurement of the posterolateral corner. *Arthroscopy* 14:489-494, 1998.
- Bowen MK, Nuber GW: Management of associated posterolateral instability in posterior cruciate ligament surgery. *Op Tech Sports Med* 1:148-153, 1993.
- Bowen MK, Warren RF, Cooper DE: Posterior cruciate ligament and related injuries. In Insall J (ed): *Surgery of the Knee*, 2nd ed. New York, Churchill Livingstone, 1993.
- Clancy WG: Posterolateral reconstruction for rotatory instability of the knee. *Video J Orthop* 7:3, 1992.
- Clancy WG, Shelbourne KD, Zoellner GB, et al: Treatment of knee joint instability secondary to rupture of the posterior cruciate ligament. Report of a new procedure. *J Bone Joint Surg Am* 65:310-322, 1983.
- Clancy WG Jr, Sutherland TB: Combined posterior cruciate ligament injuries. *Clin Sports Med* 13:629-647, 1994.
- Cooper DE: Tests for posterolateral instability of the knee in normal subjects. *J Bone Joint Surg Am* 73:30-36, 1991.
- Cooper DE, Warren RF, Warner JJP: The posterior cruciate ligament and posterolateral structures of the knee: Anatomy, function, and patterns of injury. *Instr Course Lect* 40:249-270, 1991.
- Covey DC: Current concepts review. Injuries of the posterolateral corner of the knee. *J Bone Joint Surg Am* 83:106-118, 2001.
- Covey DC, Sapega AA: Anatomy and function of the posterior cruciate ligament. *Clin Sports Med* 13:509-518, 1994.
- Covey DC, Sapega AA, Sherman GM: Testing for isometry during reconstruction of the posterior cruciate ligament. Anatomic and biomechanical considerations. *Am J Sports Med* 24:740-746, 1996.
- DeLee JC, Riley MB, Rockwood CA Jr: Acute posterolateral rotatory instability of the knee. *Am J Sports Med* 11:199-207, 1983.
- Fabricianni C, Oranski M, Zoppi U: Il muscolo popliteo, studio anatomico. *Arch Ital Anat* 87:203-217, 1982.
- Fanelli CG, Edson CJ: Management of the combined anterior cruciate ligament/posterior cruciate ligament injuries of the knee. In Chow JCY (ed): *Advanced Arthroscopy*. New York, Springer-Verlag 1999, pp 533-557.
- Fanelli GC, Giannotti BF, Edson CJ: Arthroscopically assisted combined posterior cruciate ligament/posterior lateral complex reconstruction. *Arthroscopy* 12:521-530, 1996.
- Fanelli GC, Larson RV: Practical management of posterolateral instability of the knee. *Arthroscopy* 18(2 Suppl 1):1-8, 2002.
- Fleming RE Jr, Blatz DJ, McCarroll JR: Posterior problems in the knee. Posterior cruciate insufficiency and posterolateral rotatory insufficiency. *Am J Sports Med* 9:107-113, 1981.
- Frank CB, Jackson WJ: Current concepts review: The science of reconstruction of the anterior cruciate ligament. *J Bone Joint Surg Am* 79:1556-1576, 1997.
- Gollehon DL, Torzilli PA, Warren RF: The role of the posterolateral and cruciate ligaments in the stability of the human knee. A biomechanical study. *J Bone Joint Surg Am* 69:233-242, 1987.
- Grana WA, Janssen T: Lateral ligament injury of the knee. *Orthopedics* 10:1039-1044, 1987.
- Good ES, Stowers SF, Noyes FR: Limits of movement in the human knee. Effect of sectioning the posterior cruciate ligament and posterolateral structures. *J Bone Joint Surg Am* 70:88-97, 1988.
- Harner CD, Vogrin TM, Hoher J, et al: Biomechanical analysis of a posterior cruciate ligament reconstruction. Deficiency of the posterolateral structures as a cause of graft failure. *Am J Sports Med* 28:32-39, 2000.
- Henry MH, Berend ME, Feagin JA Jr: Clinical diagnosis of acute knee ligament injuries. *Ann Chir Gynaecol* 80:120-126, 1991.
- Hughston JC: The absent posterior drawer test in some acute posterior cruciate ligament tears of the knee. *Am J Sports Med* 16:39-43, 1988.
- Hughston JC, Andrews JR, Cross MJ, Moschi A: Classification of knee ligament injuries. Part II. The lateral compartment. *J Bone Joint Surg Am* 58:173-179, 1976.
- Hughston JC, Bowden JA, Andrews JR, Norwood LA: Acute tears of the posterior cruciate ligament. Results of operative treatment. *J Bone Joint Surg Am* 62:438-450, 1980.
- Hughston JC, Jacobson KE: Chronic posterolateral rotatory instability of the knee. *J Bone Joint Surg Am* 67:351-359, 1985.
- Hughston JL, Norwood LA: The posterolateral drawer test and external rotation recurvatum test for posterolateral rotatory instability of the knee. *Clin Orthop* 147:82-87, 1980.
- Insall JN, Hood RW: Bone-block transfer of the medial head of the gastrocnemius for posterior cruciate insufficiency. *J Bone Joint Surg Am* 64:691-699, 1982.
- Jacobson KE: Technical pitfalls of collateral ligament surgery. *Clin Sports Med* 18:847-882, 1999.
- Jakob RP, Hassler H, Stäubli HU: Observations on rotatory instability of the lateral compartment of the knee: Experimental studies on the functional anatomy and pathomechanism of the true and reverse pivot shift sign. *Acta Orthop Scand Suppl* 191:1-32, 1981.
- Jakob RP, Warner JP: Lateral and posterolateral rotatory instability of the knee. In Jakob RP, Stäubli HU (eds): *The Knee and the Cruciate Ligaments: Anatomy, Biomechanics, Clinical Aspects, Reconstruction, Complications, Rehabilitation*. New York, Springer, 1992, pp 463-494.
- Johansson H: Role of knee ligaments in proprioception and regulation of muscle stiffness. *J Electromyogr Kinesiol* 1:158-179, 1991.
- Kannus P: Nonoperative treatment of grade II and III sprains of the lateral ligament compartment of the knee. *Am J Sports Med* 17:83-88, 1989.
- Kennedy JC, Alexander IJ, Hayes KC: Nerve supply of the human knee and its functional importance. *Am J Sports Med* 10:329-335, 1982.
- Kim SJ, Shin, SJ, Jeong JH: Posterolateral rotatory instability treated by a modified biceps rerouting technique: Technical considerations and results in cases with and without posterior cruciate ligament insufficiency. *Arthroscopy* 19:493-499, 2003.
- Krukhaug Y, Molster A, Rodt A, Strand T: Lateral ligament injuries of the knee. *Knee Surg Sports Traumatol Arthrosc* 6:21-25, 1998.
- LaPrade RF, Gilbert TJ, Bollom TS, et al: The magnetic resonance imaging appearance of individual structures of the posterolateral knee. A prospective study of normal knees and knees with surgically verified grade III injuries. *Am J Sports Med* 28:191-199, 2000.
- LaPrade RF, Hamilton CD, Engebretsen L: Treatment of acute and chronic combined anterior cruciate ligament and posterolateral knee injuries. *Sports Med Arthrosc Rev* 5:91-99, 1997.
- LaPrade RF, Resig S, Wentorf F, Lewis JL: The effects of grade III posterolateral knee complex injuries on anterior cruciate ligament graft force. A biomechanical analysis. *Am J Sports Med* 27:469-475, 1999.
- LaPrade RF, Terry GC: Injuries to the posterolateral aspect of the knee. Association of anatomic injury patterns with clinical instability. *Am J Sports Med* 25:433-438, 1997.
- Last RJ: The popliteus muscle and lateral meniscus. With a note on the attachment of the medial meniscus. *J Bone Joint Surg Br* 32:93-99, 1950.
- Latimer HA, Tibone JE, El Attrache NS, et al: Reconstruction of the lateral collateral ligament of the knee with patellar tendon allograft. Report of a new technique in combined ligament injuries. *Am J Sports Med* 26:656-662, 1998.
- Lee MC, Park YK, Lee SH, et al: Posterolateral reconstruction using split Achilles tendon allograft. *Arthroscopy* 19:1043-1049, 2003.
- Lipscomb AB, Anderson AF, Norwig ED, et al: Isolated posterior cruciate ligament reconstruction. Long-term results. *Am J Sports Med* 21:490-496, 1993.
- Markolf KL, Wascher DC, Finerman GAM: Direct in vitro measurement of forces in the cruciate ligaments. Part II: The effect of section of the posterolateral structures. *J Bone Joint Surg Am* 75:387-394, 1993.
- Maynard MJ, Deng X, Wickiewicz TL, Warren RF: The popliteofibular ligament. Rediscovery of a key element in posterolateral stability. *Am J Sports Med* 24:311-316, 1996.
- McGuire DA, Wolchok JC: Extra-articular lateral reconstruction technique. *Arthroscopy* 16:553-557, 2000.

SECTION V Ligament Injuries

53. McGuire DA, Wolchok JW: Posterolateral corner reconstruction. *Arthroscopy* 19:790-793, 2003.
54. Miller TT, Gladden P, Staron RB, et al: Posterolateral stabilizers of the knee: Anatomy and injuries assessed with MR imaging. *AJR Am J Roentgenol* 169:1641-1647, 1997.
55. Nielsen S, Helmig P: The static stabilizing function of the popliteal tendon in the knee. An experimental study. *Arch Orthop Trauma Surg* 104:357-362, 1986.
56. Nielsen S, Helmig P: Posterior instability of the knee joint. An experimental study. *Arch Orthop Trauma Surg* 105:121-125, 1986.
57. Nielsen S, Ovesen J, Rasmussen O: The posterior cruciate ligament and rotatory knee instability. An experimental study. *Arch Orthop Trauma Surg* 104:53-56, 1985.
58. Nielsen S, Rasmussen O, Ovesen J, Andersen K: Rotatory instability of cadaver knees after transection of collateral ligaments and capsule. *Arch Orthop Trauma Surg* 103:165-169, 1984.
59. Noyes FR: PCL & posterolateral complex injuries. Overview. *Am J Knee Surg* 9:171, 1996.
60. Noyes FR, Barber-Westin SD: Surgical reconstruction of severe chronic posterolateral complex injuries of the knee using allograft tissues. *Am J Sports Med* 23:2-12, 1995.
61. Noyes FR, Barber-Westin SD: Surgical restoration to treat chronic deficiency of the posterolateral complex and cruciate ligaments of the knee joint. *Am J Sports Med* 24:415-426, 1996.
62. Noyes FR, Grood ES, Torzilli PA: Current concepts review. The definitions of terms for motion and position of the knee and injuries of the ligaments. *J Bone Joint Surg Am* 71:465-472, 1989.
63. Noyes FR, Stowers SE, Grood ES, et al: Posterior subluxations of the medial and lateral tibiofemoral compartments. An in vitro sectioning study in cadaveric knees. *Am J Sports Med* 21:407-414, 1993.
64. Pavlovich RI, Nafarrate EB: Trivalent reconstruction for posterolateral and lateral knee instability. *Arthroscopy* 18:E1, 2002.
65. Ross G, Chapman AW, Newberg AR, Scheller AD Jr: Magnetic resonance imaging for the evaluation of acute posterolateral complex injuries of the knee. *Am J Sports Med* 25:444-448, 1997.
66. Sapega AA, Covey DC: The biomechanics of femoral and tibial posterior cruciate ligament graft placement. *Clin Sports Med* 13:553-559, 1994.
67. Scapinelli R: Studies on the vasculature of the human knee joint. *Acta Anat* 70:305-331, 1968.
68. Seebacher JR, Inglis AE, Marshall JL, et al: The structure of the posterolateral aspect of the knee. *J Bone Joint Surg Am* 64:536-541, 1982.
69. Segond P: Pathologie externe. Recherches cliniques et expérimentales sur les épanchements sanguins du genou par entorse. *Progres Med (Paris)* 7:297-299, 1879.
70. Shindell R, Walsh WM, Connolly JF: Avulsion fracture of the fibula: "The arcuate sign" of posterolateral knee instability. *Nebr Med J* 69:369-371, 1984.
71. Sidles JA, Larson RV, Garbini JL, et al: Ligament length relationships in the moving knee. *J Orthop Surg* 6:593-610, 1988.
72. Skyhar MJ, Warren RE, Ortiz GJ, et al: The effects of sectioning of the posterior cruciate ligament and the posterolateral complex on the articular contact pressures within the knee. *J Bone Joint Surg Am* 75:694-699, 1993.
73. Smith BA, Livesay GA, Woo SL-Y: Biology and biomechanics of the anterior cruciate ligament. *Clin Sports Med* 12:637-670, 1993.
74. Staubli HU, Birrer S: The popliteus tendon and its fascicles at the popliteal hiatus: Gross anatomy and functional arthroscopic evaluation with and without anterior cruciate ligament deficiency. *Arthroscopy* 6:209-220, 1990.
75. Strand T, Molster AO, Engesaeter LB, et al: Primary repair in posterior cruciate ligament injuries. *Acta Orthop Scand* 55:545-547, 1984.
76. Sudasna S, Harnsiriwattanagit K: The ligamentous structures of the posterolateral aspect of the knee. *Bull Hosp Jt Dis Orthop Inst* 50:35-40, 1990.
77. Tardieu M, Lazennec JY, Christel P, et al: [Normal and pathological MRI aspects of the posterolateral corner of the knee.] *J Radiol* 76:605-609, 1995.
78. Terry GC, LaPrade RF: The posterolateral aspect of the knee. Anatomy and surgical approach. *Am J Sports Med* 24:732-739, 1996.
79. Terry GC, Norwood LA, Hughston JC, Caldwell KM: How iliotibial tract injuries of the knee combine with acute anterior cruciate ligament tears to influence abnormal anterior tibial displacement. *Am J Sports Med* 21:55-60, 1993.
80. Torg JS, Conrad W, Kalen V: Clinical diagnosis of anterior cruciate ligament instability in the athlete. *Am J Sports Med* 4:84-93, 1976.
81. Towne LC, Blazina ME, Marmor L, Lawrence JF: Lateral compartment syndrome of the knee. *Clin Orthop* 76:160-168, 1971.
82. Veltri DM, Deng XH, Torzilli PA, et al: The role of the cruciate and posterolateral ligaments in stability of the knee. A biomechanical study. *Am J Sports Med* 23:436-443, 1995.
83. Veltri DM, Warren RF: Posterolateral instability of the knee. *Instr Course Lect* 44:441-453, 1995.
84. Vladimirov B: Arterial sources of blood supply of the knee-joint in man. *Nauchni Tr Vissh Med Inst Sofia* 47:1-10, 1968.
85. Wascher DC, Grauer JD, Markoff KL: Biceps tendon tenodesis for posterolateral instability of the knee. An in vitro study. *Am J Sports Med* 21:400-406, 1993.
86. Wascher DC, Markolf KL, Shapiro MS, Finerman GA: Direct in vitro measurement of forces in the cruciate ligaments. Part I: The effect of multiplane loading in the intact knee. *J Bone Joint Surg Am* 75:377-386, 1993.
87. Watanabe Y, Moriya H, Takahashi K, et al: Functional anatomy of the posterolateral structures of the knee. *Arthroscopy* 9:57-62, 1993.
88. Westrich GH, Hannafin JA, Potter HG: Isolated rupture and repair of the popliteus tendon. *Arthroscopy* 11:628-632, 1995.
89. Wirth CJ, Jager M: Dynamic double tendon replacement of the posterior cruciate ligament. *Am J Sports Med* 12:39-43, 1984.
90. Wright DG, Covey DC, Born CT, Sadasivan KK: Open dislocation of the knee. *J Orthop Trauma* 9:135-140, 1995.
91. Wroble RR, Grood ES, Cummings JS, et al: The role of the lateral extraarticular restraints in the anterior cruciate ligament-deficient knee. *Am J Sports Med* 21:257-262, 1993.
92. Yu JS, Salonen DC, Hodler J, et al: Posterolateral aspect of the knee: Improved MR imaging with a coronal oblique technique. *Radiology* 198:199-204, 1996.
93. Zimny ML: Mechanoreceptors in articular tissues. *Am J Anat* 182:16-32, 1988.