

## Technical Note

# Posterolateral Corner Reconstruction

David A. McGuire, M.D., and Jeffrey C. Wolchok, M.S.

---

**Abstract:** One should suspect a compromise of the lateral structures when presented with a posterior cruciate ligament (PCL) injury, especially if grade III laxity is present. In our experience, if a combined injury to the PCL and posterolateral corner is diagnosed, a combined PCL and posterolateral reconstruction is needed to restore stability. This article describes a posterolateral reconstruction procedure. This procedure, when used in combination with an intra-articular PCL reconstruction, restores rotary and posterior knee stability. This procedure uses allograft tissue and interference screw fixation, although autograft tissue may be used. **Key Words:** PCL reconstruction—Posterolateral corner—Allografts.

---

Despite some significant improvements, posterior cruciate ligament (PCL) reconstructions have not fared as well as anterior cruciate ligament (ACL) reconstructions. Reasons given have included native PCL ligament anisometry,<sup>1</sup> inadequate graft material, and the difficulty in reconstructing the graft with a single bundle technique.<sup>2,3</sup> Another cause may be the failure to diagnose and address posterolateral corner injuries.

Patients presenting with grade I posterior laxity are generally best treated nonsurgically.<sup>4</sup> However, when grade III posterior laxity and functional instability are present, surgical treatment may be required. The increased laxity and functional instability seen in these patients are often the result of a combined injury to the PCL and posterolateral corner.<sup>5,6</sup> With a combined injury, an isolated PCL reconstruction will not restore normal motion patterns.<sup>7</sup> Additionally, failure to address posterolateral instability will lead to increased strain<sup>7</sup> on the reconstructed graft. Over time, this

strain can lead to lengthening and laxity. Therefore, if a PCL reconstruction is undertaken in these patients, it should be combined with a posterolateral reconstruction.

In this technical note, we describe a surgical method for reconstruction of the posterolateral corner that uses a semitendinosus allograft and bioabsorbable interference screws. We believe this technique may cause less surgical morbidity than other methods.

## SURGICAL TECHNIQUE

### Posterolateral Reconstruction

A lateral incision is made through the subcutaneous tissue from the lateral femoral epicondyle to the posterior aspect of the fibular head. The fascia lata is divided longitudinally. To establish the proximal tunnel, a site just anterior to the lateral collateral ligament is identified (Figs 1 and 2). A slot-eyed guide pin is placed in this position. The pin and subsequent tunnel should be oriented in a proximal medial direction. The foot is then internally rotated, thereby exposing the head of the fibula. To establish the fibular tunnel, a pin is drilled obliquely, angling from posterior proximal to anterior distal and exiting through the skin anteriorly (Figs 1 and 2). Drilled in this fashion, the pin is a safe distance from the peroneal nerve. The posteroproximal to anterodistal orientation keeps the pin par-

---

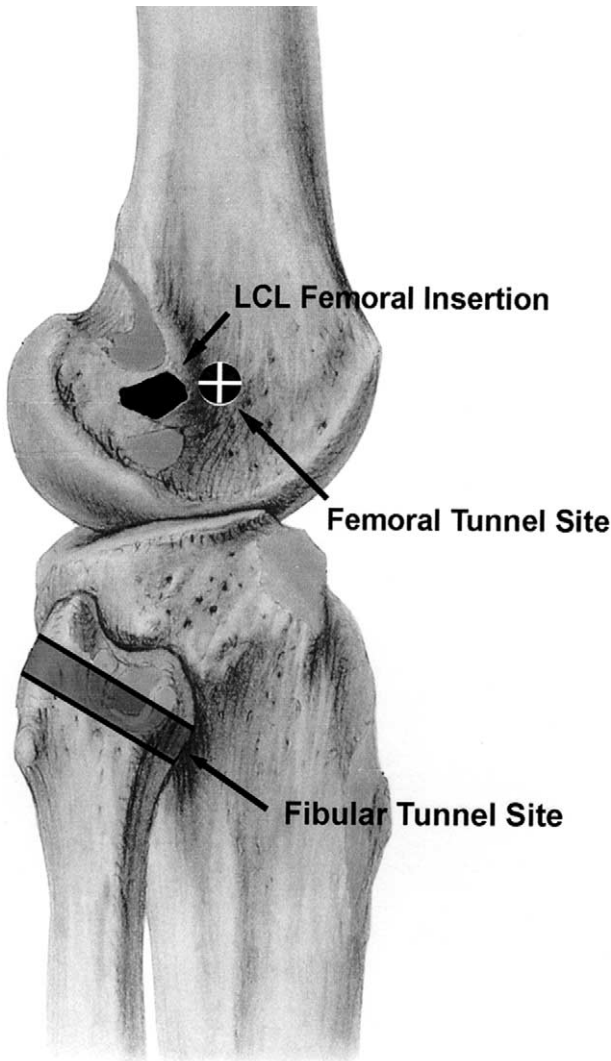
*From the Clinical Faculty, Orthopedics and Sports Medicine, University of Washington (D.A.M.), Seattle, Washington; and Alaska Orthopedic Lab (J.C.W.), Anchorage, Alaska, U.S.A.*

*Address correspondence and reprint requests to Jeffrey C. Wolchok, M.S., c/o David A. McGuire, M.D., 4100 Lake Otis Pkwy, No. 320, Anchorage, AK 99508, U.S.A. E-mail: jeff@mcguiremd.com*

*© 2003 by the Arthroscopy Association of North America*

*0749-8063/03/1907-3433\$30.00/0*

*doi:10.1016/S0749-8063(03)00387-6*

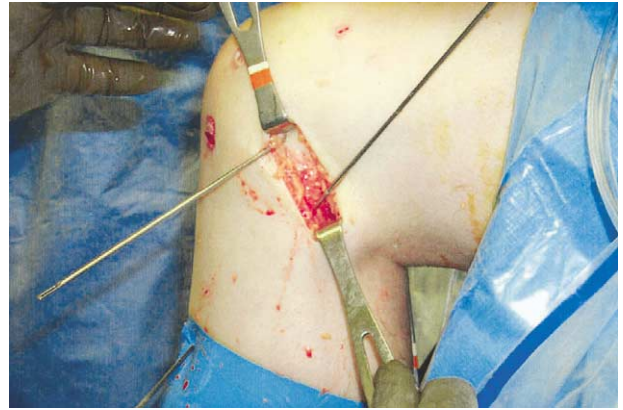


**FIGURE 1.** Tunnels are placed at a site just anterior to the femoral attachment of the LCL and the posterior aspect of the fibular head. A graft placed in this position will approximate the static portion of the popliteus tendon.

allel to the peroneal nerve as it is drilled (Fig 3). For added safety, the incision may be enlarged, and the peroneal nerve can be visualized and isolated.

Initially, the pins are drilled a short distance into the bone. A suitably strong suture material is stretched between these 2 pins. The knee is then put through a full range of motion. Strain changes in sutures placed in this way should be less than 2 mm.

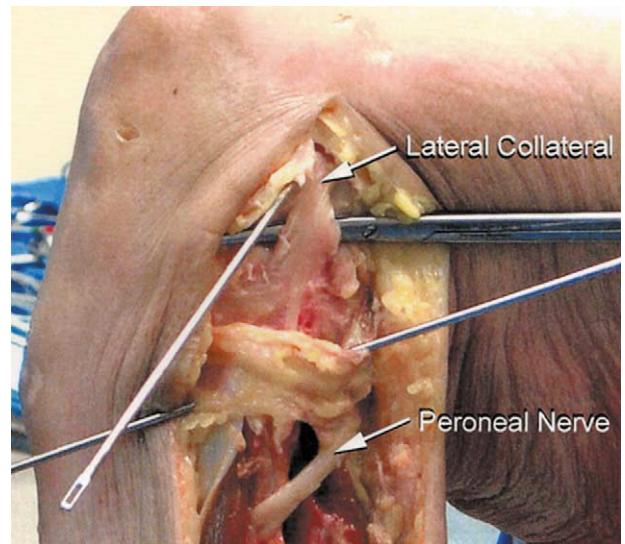
This is a simple but useful approximation of isometry. If the strain in the suture is inadequate or the suture breaks, indicating a nonisometric position, the pins are reinserted at a more suitable site until satis-



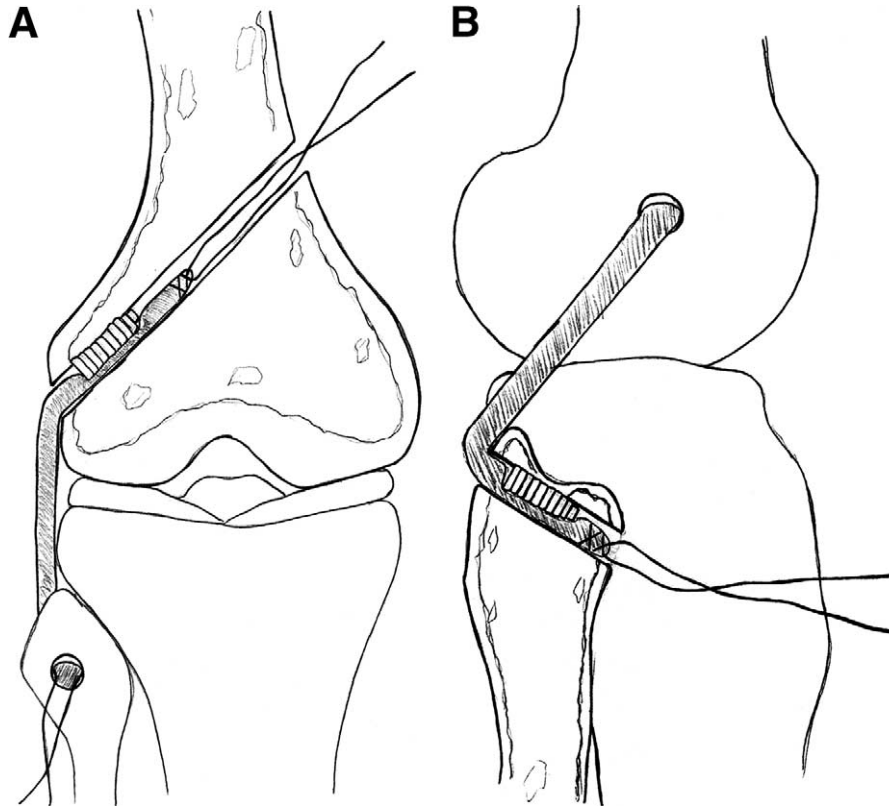
**FIGURE 2.** The fibular guide pin is directed obliquely, angling from posterior proximal to anterior distal, and exiting through the skin anteriorly. If excursion between the 2 pins is satisfactory (< 2 mm), the tunnels are completed with a 7-mm cannulated reamer.

factory isometry is established. The work of Sidles and Larsen<sup>1</sup> established that no truly isometric positions exist laterally and extra-articularly. However, this method establishes a useful approximation. Once adequate pin position is achieved, a 7-mm cannulated reamer is advanced over each pin. On the femoral side, the drill is advanced to and then through the medial femoral cortex. Likewise, the fibular tunnel is drilled through, exiting the fibular head anterodistally.

The graft is prepared at a side table. To minimize donor site morbidity, a semitendinosus allograft may



**FIGURE 3.** As seen in this dissection, the posteroproximal to anterodistal orientation of the fibular tunnel keeps the pin parallel to the peroneal nerve as it is drilled.



**FIGURE 4.** Both the (A) femoral and (B) fibular tunnels are typically drilled through. With tension applied to the graft, tendon to bone fixation is accomplished with bioabsorbable interference screws.

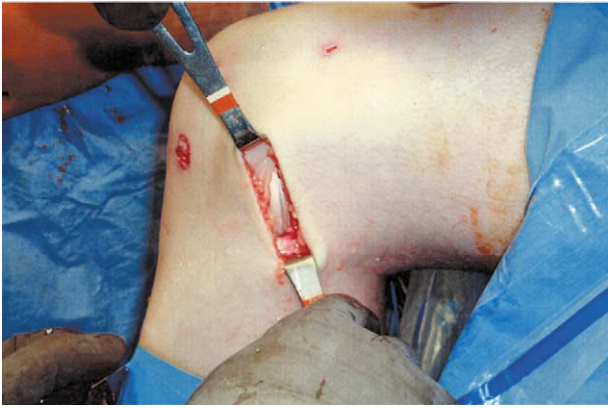
be used. However, if allograft tissue is not available, autologous tissue may be substituted. To allow adequate interference screw fixation, at least 25 mm of graft should be positioned within the tunnels. Therefore, the appropriate graft length is the distance between the femoral and fibular tunnels plus an additional 50 mm to allow fixation within the tunnels. A running locking stitch or whip stitch is used at each end to allow graft passage and tensioning.

The graft sutures are then advanced into the tunnels with the aid of the slot-eyed guide pins. With the knee held in 90° of flexion, approximately 5 kg of tension is applied to both ends of the graft. Direct tendon to bone fixation is accomplished with 7 × 20 mm bioabsorbable interference screws placed over a guide wire. Under tension, the femoral insertion is fixed first, followed by the fibular insertion (Figs 4 and 5). Stability is then checked. Abnormal exterior rotational laxity, as shown with the dial test, should be eliminated. The wound is then closed with sub-cuticular absorbable sutures.

### Rehabilitation Program

The postoperative program is typically dictated by the concomitant cruciate ligament reconstruction, which is typically a PCL reconstruction. After a combined PCL and posterolateral reconstruction, a postoperative hinged brace is used for 8 weeks. The brace range of motion (ROM) limits progress from 10° extension and 45° flexion during the first week to 0° and 60° during week 2; 0° and 90° during week 3; and 0° and 120° from week 4 on. The knee is maintained in extension except during ROM exercises.

Range of motion exercises should initially be limited to a continuous passive motion (CPM) device and progress to passive assisted heel-slides at day 6. The CPM device is used for the first 5 days. CPM ROM is increased from 10° and 45° (extension and flexion, respectively, initially, to 5° and 60° at day 3. Bracing the knee during ROM exercises is important to protect the graft during the first 6 weeks. The patient should be kept partial-weight-bearing for the first week and



**FIGURE 5.** After fixation, the knee is cycled through a full range of motion. Tension should remain in the graft throughout.

progress to full weight-bearing in extension as pain permits.

A compressive cold therapy cuff is used for the first 2 weeks.<sup>8</sup> Cold therapy is applied continuously for the first 4 days and then as needed until week 2. Postoperative pain and inflammation are controlled with oral medication. Toradol is administered intraoperatively and orally, 10 mg, every 6 hours. Narcotics such as hydrocodone with acetaminophen can be used as supplementary medication. This regimen has largely eliminated the need for patient-controlled anesthesia devices. However, in some cases these can be used as well.

## DISCUSSION

Importantly, an injury to the PCL is often associated with a complex injury mechanism rather than an isolated posterior force. With this in mind, it is important to realize that both acute and chronic tears may involve a more complex injury than initially considered. The other soft tissue restraints within the knee may be injured. Specifically, the lateral structures and, in particular, the popliteus tendon may be compromised. In such instances, these secondary restraints to external tibial rotation may be so damaged that an isolated PCL reconstruction using any graft source may fail.

Several surgical techniques have been developed to treat posterolateral injuries.<sup>6,9-12</sup> These have included advancement of the osseous attachment of the arcuate ligament complex,<sup>6</sup> proximal advancement of the posterolateral complex,<sup>9</sup> biceps tenodesis,<sup>10</sup> and posterolateral sling.<sup>11</sup> Each of these techniques has had modest success.

The reconstruction technique described in this paper

approximates the anatomy of the static portion of the popliteus tendon (popliteofibular ligament). Recent studies<sup>13-15</sup> have shown that the popliteofibular ligament is an important restraint to external knee rotation. For this reason, other researchers<sup>15</sup> and we believe that a popliteofibular ligament reconstruction should be incorporated in any surgical technique used to correct posterolateral knee instability. Additionally, we believe the use of allograft material and the minimal disruption of the native posterolateral structures makes this procedure a low morbidity alternative. Further research will help determine whether additional procedures are needed.

## REFERENCES

1. Sidles JA, Larson RV, Gabrini JL, et al. Ligament length relationships in the moving knee. *J Orthop Res* 1988;6:583-610.
2. Race A, Amis AA. PCL reconstruction: In vitro biomechanical comparison of isometric versus single and double-bundled anatomic grafts. *J Bone Joint Surg Br* 1998;80:173-179.
3. Harner CD, Jansushak MA, Kanamori A, et al. Biomechanical analysis of a double-bundle posterior cruciate ligament reconstruction. *Am J Sports Med* 2000;28:144-151.
4. Bergfeld JA, Leyes M, Calabrese GJ. Nonoperative treatment of posterior cruciate ligament injuries. In: Fanelli GC, ed. *Posterior cruciate ligament injuries: A practical guide to management*. New York: Springer-Verlag, 2001;117-134.
5. Baker CL, Norwood LA, Hughston JC. Acute combined posterior cruciate and posterolateral instability of the knee. *Am J Sports Med* 1984;12:204-208.
6. Hughston JC, Jacobsen KE. Chronic posterolateral rotatory instability of the knee. *J Bone Joint Surg Am* 1985;67:351-359.
7. Cooley VJ, Larson RV, Harrington RM. Effect of lateral ligament reconstruction on intra-articular posterior cruciate ligament graft forces and knee motion. *Univ Wash Orthop Res Rep* 1996;37-41.
8. Barber FA, McGuire DA, Glick S. Continuous cold flow therapy for outpatient anterior cruciate ligament reconstruction. *Arthroscopy* 1998;14:130-135.
9. Noyes FR, Barber-Westin SD. Surgical restoration to treat chronic deficiency of the posterolateral complex and cruciate ligaments of the knee. *Am J Sports Med* 1996;24:415-426.
10. Fanelli GC, Giannotti BF, Edson CJ. Arthroscopically assisted combined posterior cruciate ligament/posterior lateral complex reconstruction. *Arthroscopy* 1996;12:521-530.
11. Albright JP, Brown AW. Management of chronic posterolateral rotatory instability of the knee: Surgical technique for the posterolateral corner sling procedure. *Instr Course Lect* 1998; 47:369-378.
12. Larson RV, Sidles JA, Beals TC. Isometry of the lateral collateral and popliteofibular ligaments and a technique for reconstruction. *Univ Wash Orthop Res Rep* 1996;42-44.
13. Veltri DM, Deng XH, Torzilli PA, et al. The role of the popliteofibular ligament in stability of the human knee: A biomechanical study. *Am J Sports Med* 1996;24:19-27.
14. Shahane SA, Ibbotson R, Strachan R, Bikerstaff DR. The popliteofibular ligament: An anatomic study of the posterolateral corner of the knee. *J Bone Joint Surg Br* 1999;81:636-642.
15. Sugita T, Amis AA. Anatomic and biomechanical study of the lateral collateral and popliteofibular ligaments. *Am J Sports Med* 2001;29:466-472.